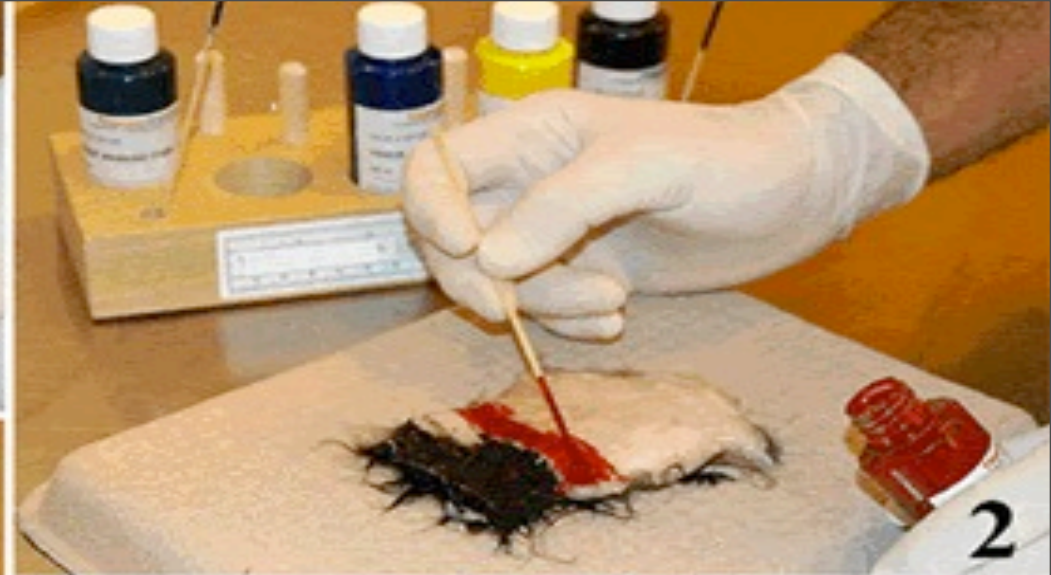
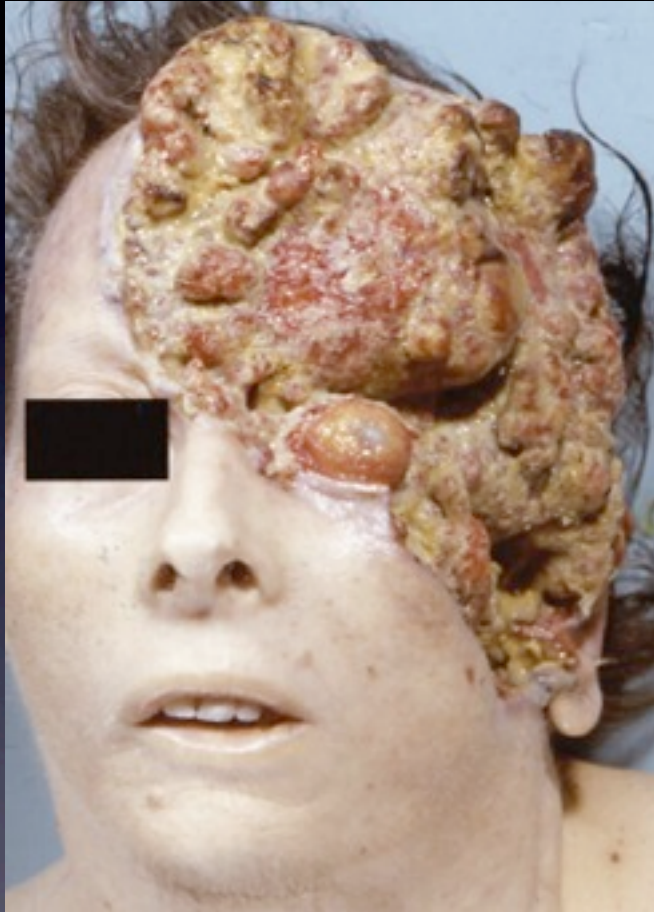
Margins of Resection for Skin Cancers

Paul K. Shitabata, M.D.
Dermatopathology Institute



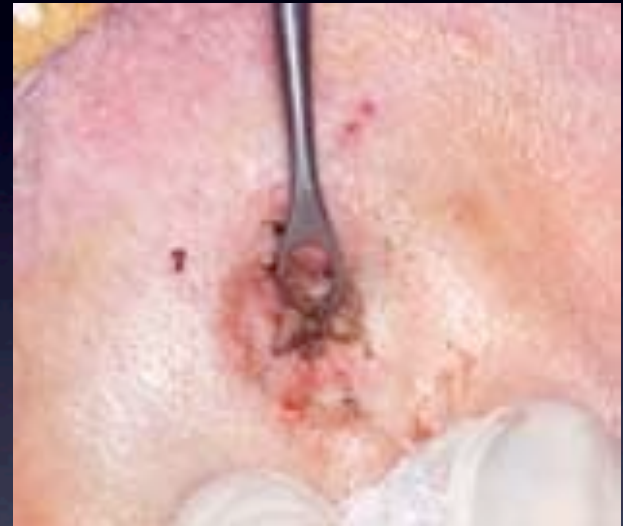Background



- BCC-1,000,000 cases
- SCC-250,000 cases
- Incidence nearly equal to all other cancers combined

ED and C

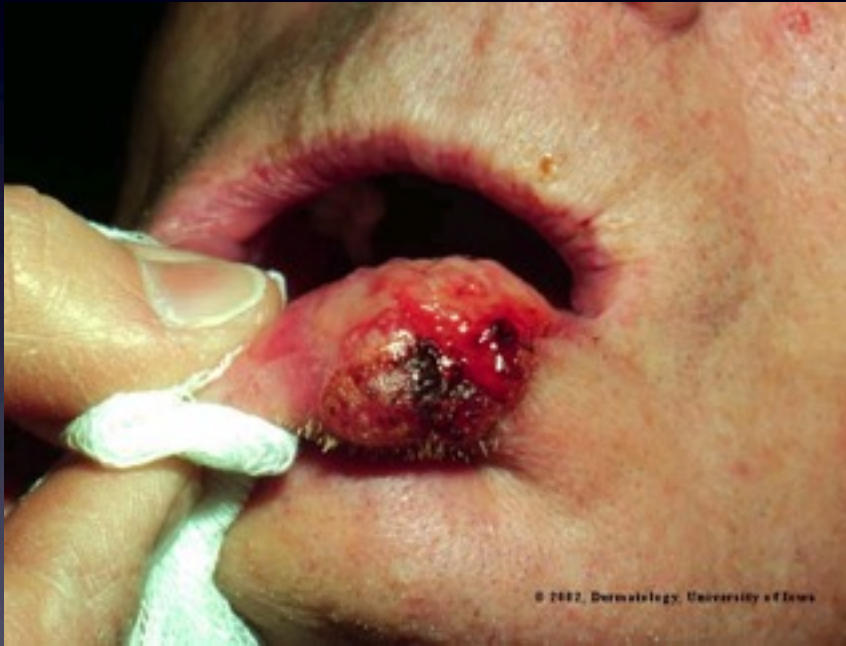- Tx failure associated with tumor location in high risk area (head and neck esp. centrofacial area)
- If subq fat penetrated with curette, recommended procedure converted to excision
- Aggressive curettage may be performed followed by excision 0.2 cm from the border of the erosion for ill-defined tumors (98% cure)



BCC

<p>Low Risk <2 cm Favorable histology</p>	<p>0.4 cm margin 95% 5 YR cure</p>
<p>High Risk >2 cm Aggressive histology Mask facial, genitalia, hands/feet</p>	<p>MOHS Excision with FS control</p>

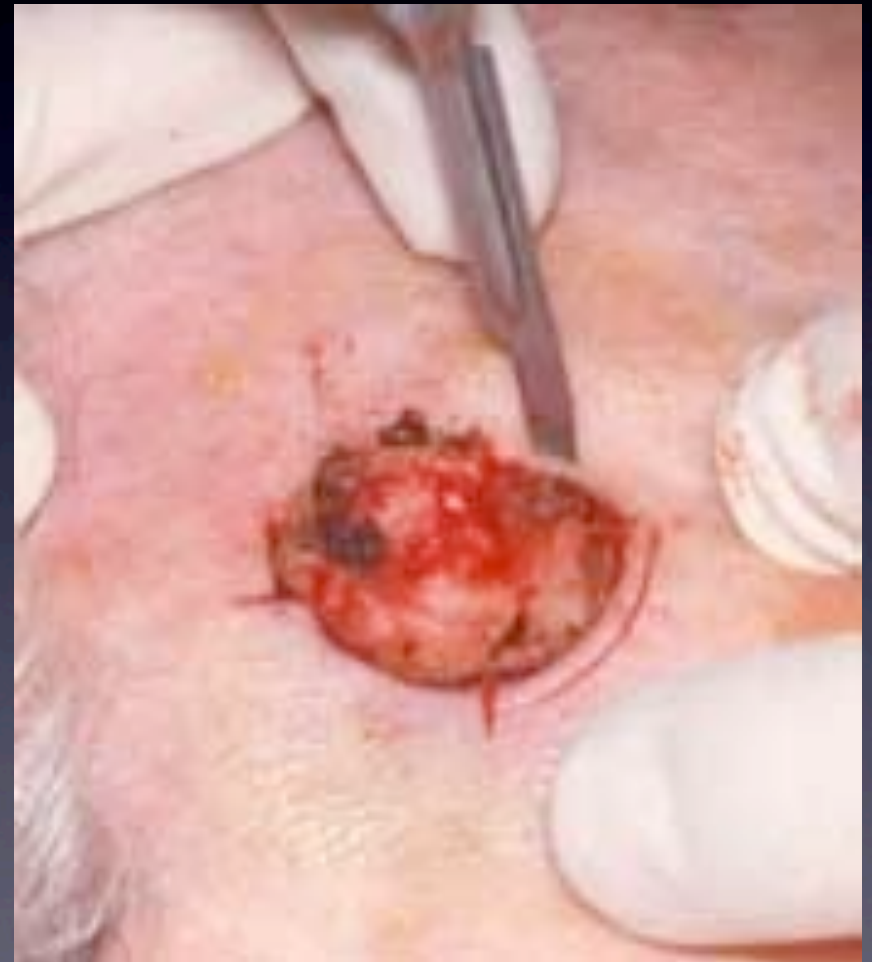SCC Metastasis Risk Factors



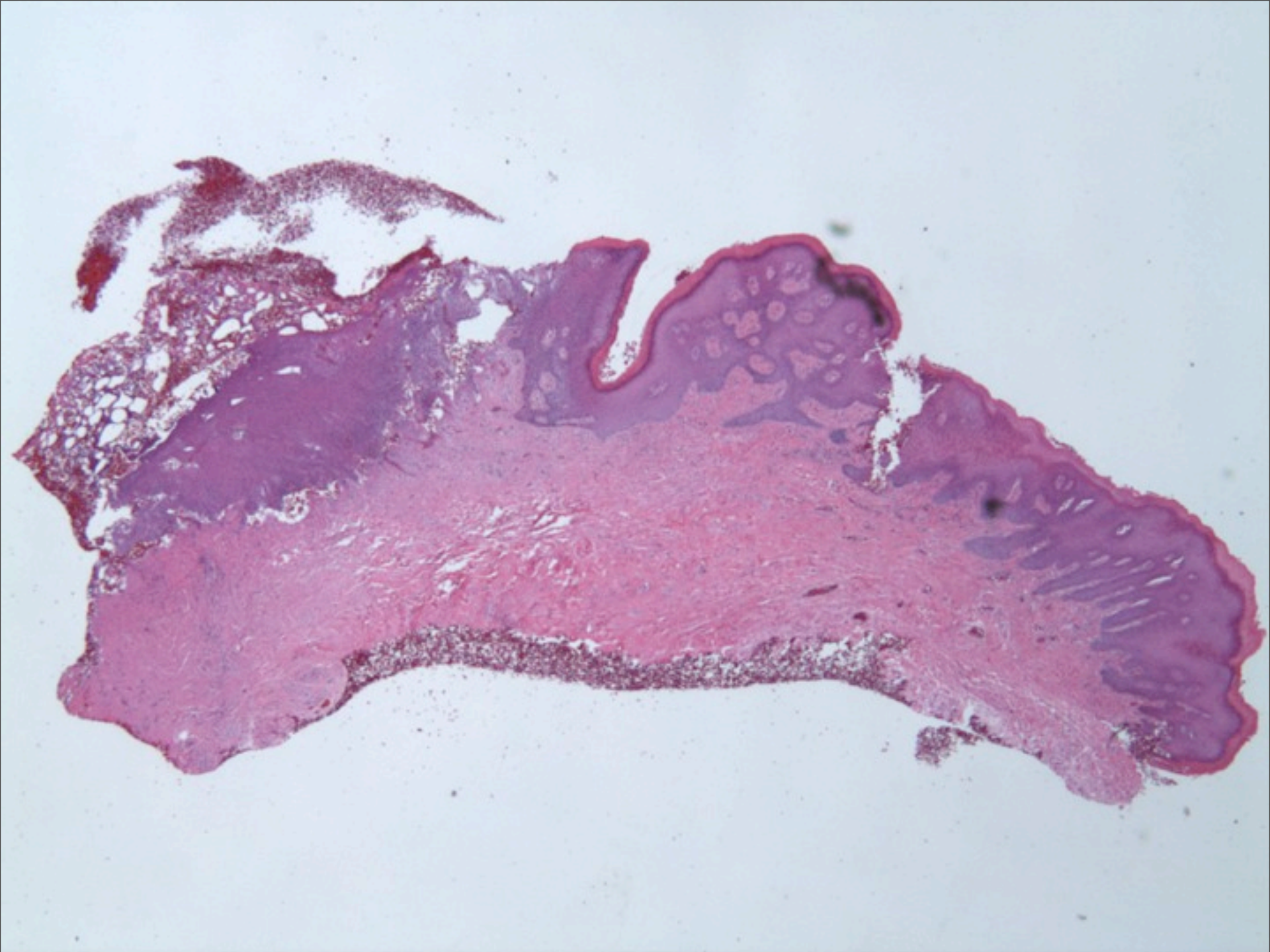
- Ill defined borders
- Diameter >2 cm
- Poorly differentiated tumors
- High risk areas (face, genitalia, hands, and feet)
- Recurrent tumors
- Invasion into subq fat
- Greater vertical depth

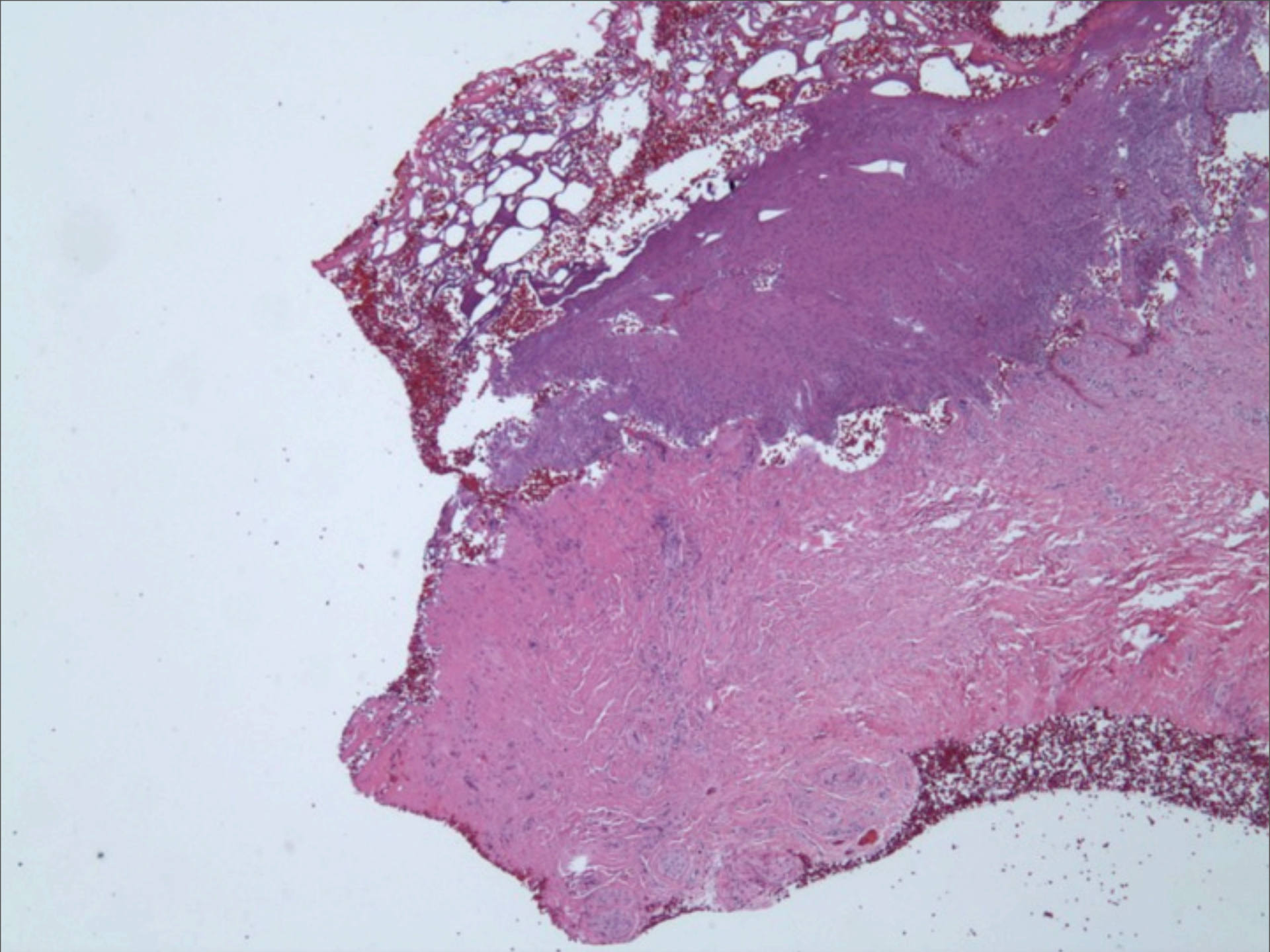
SCC Excision and Margins

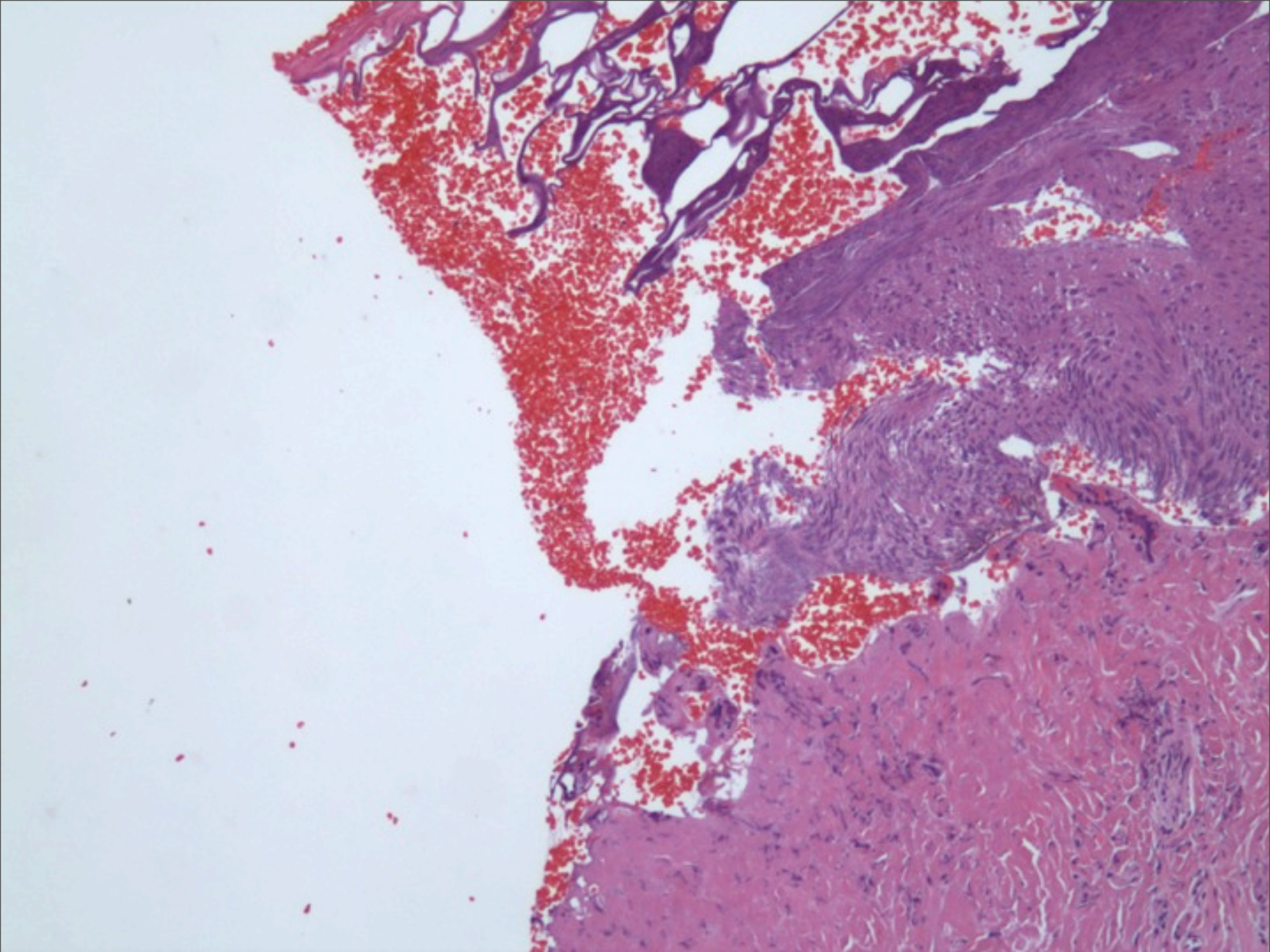
Low Risk	0.4 cm margin 95% 5 YR cure
High Risk	MOHS Excision with FS control

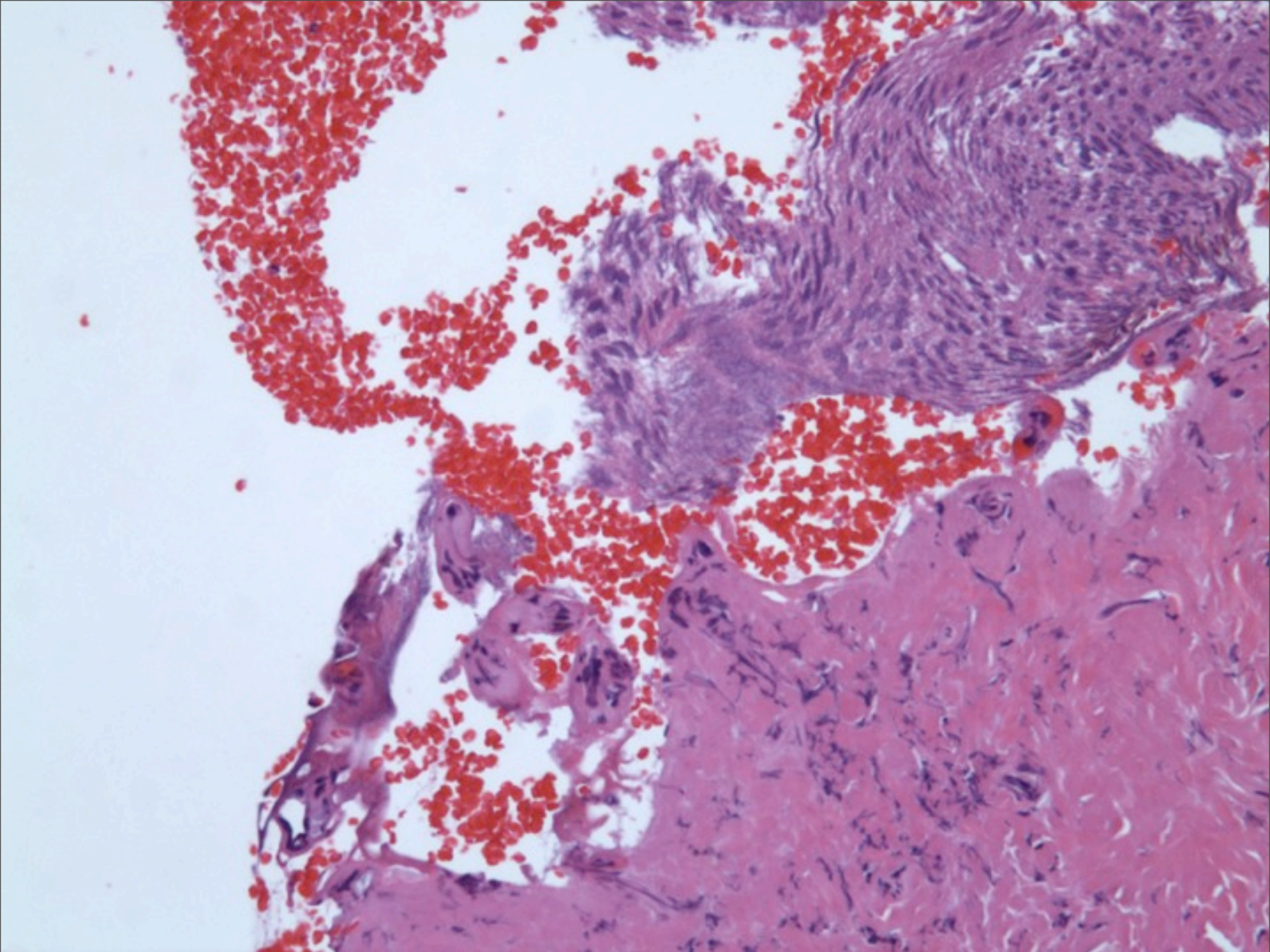


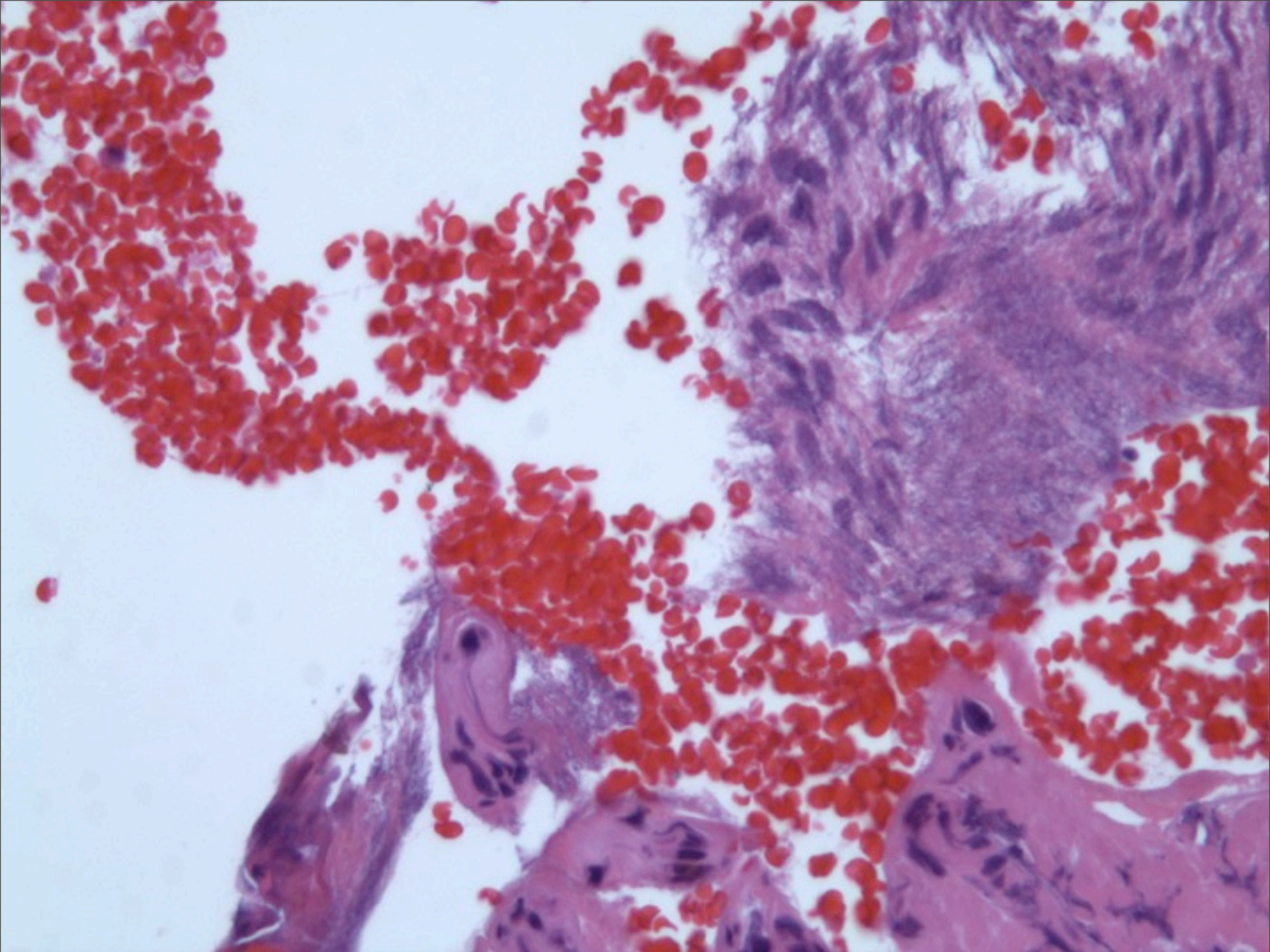
Should Not Report as Completely
Excised if...



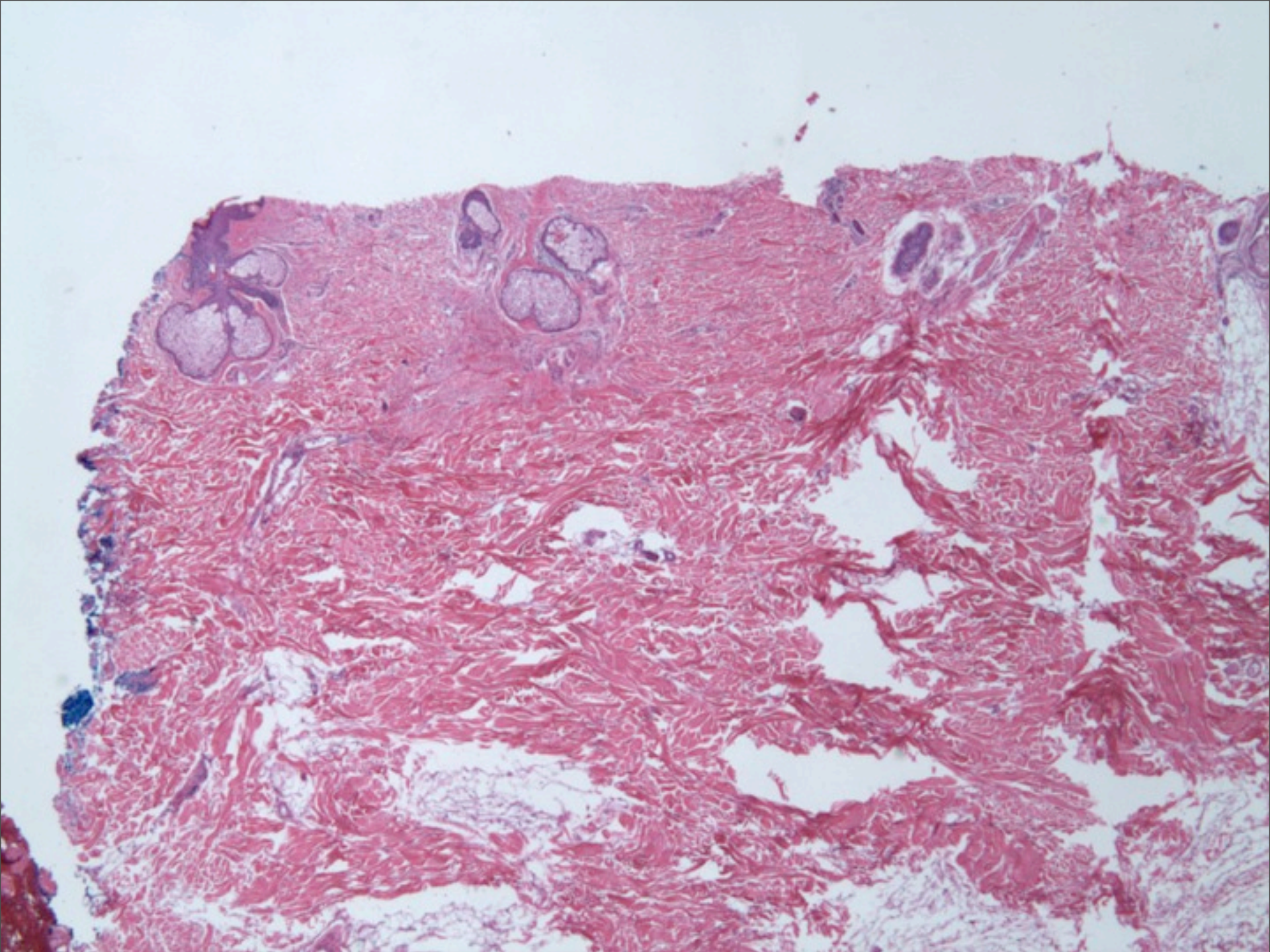


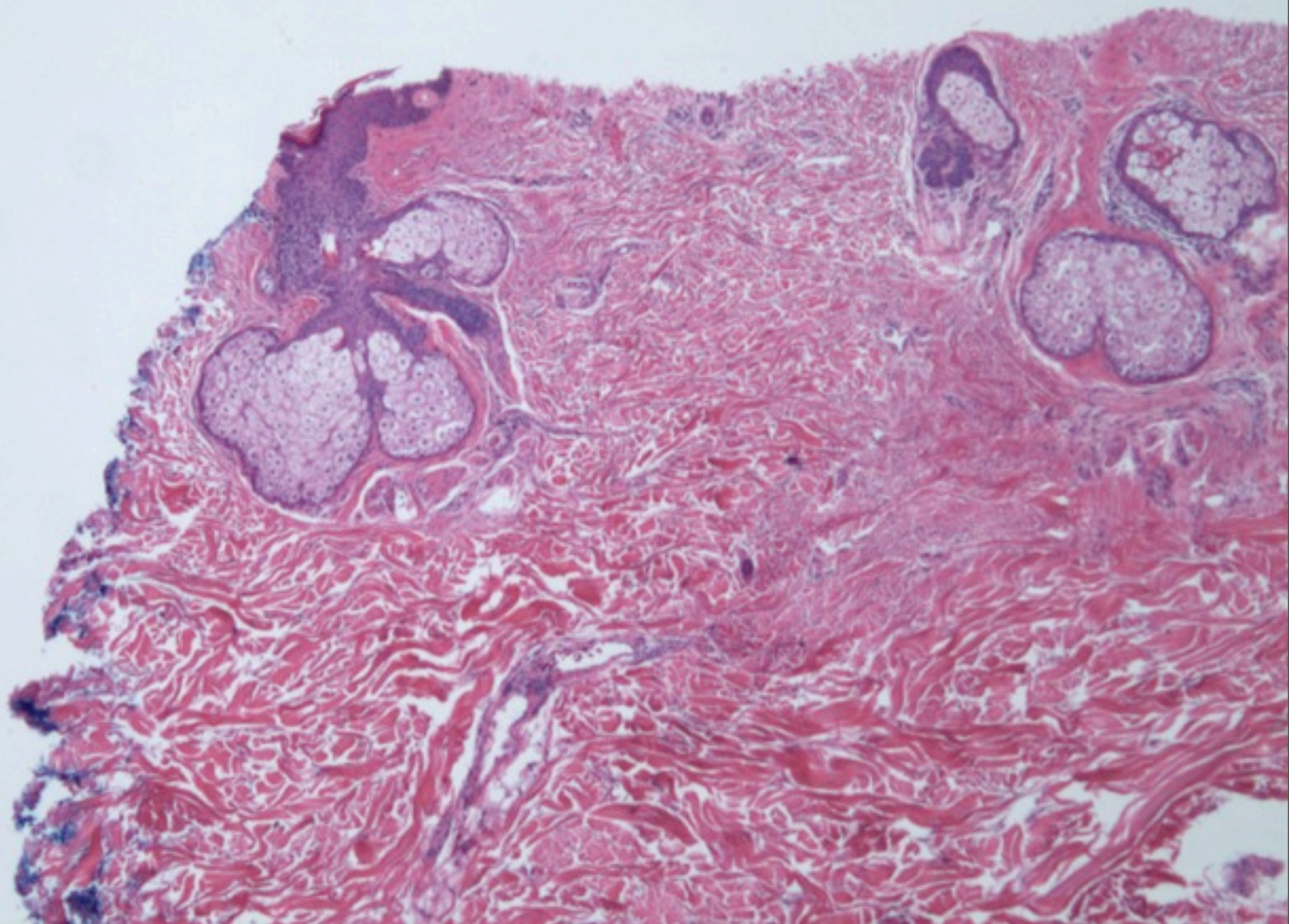


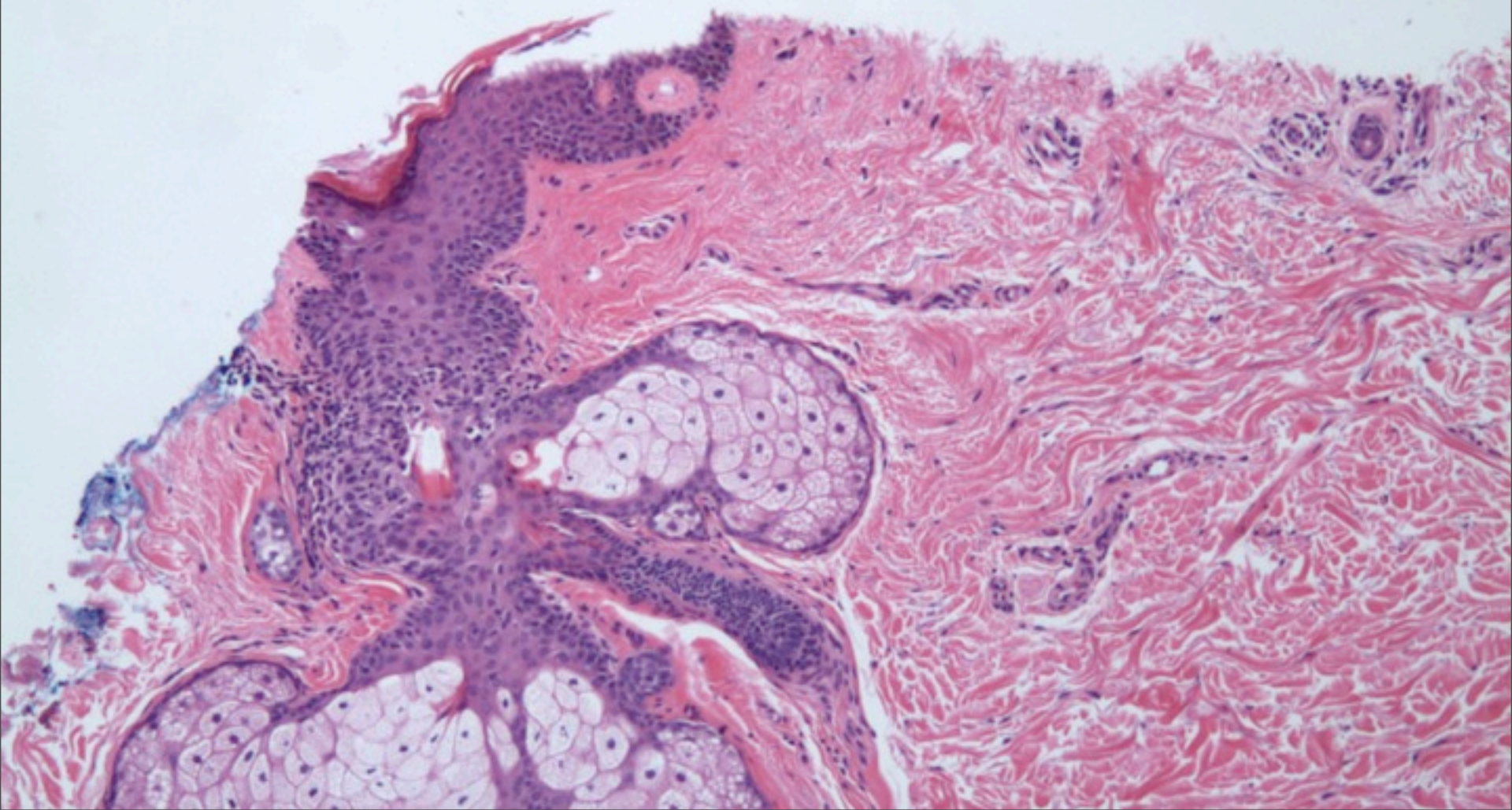




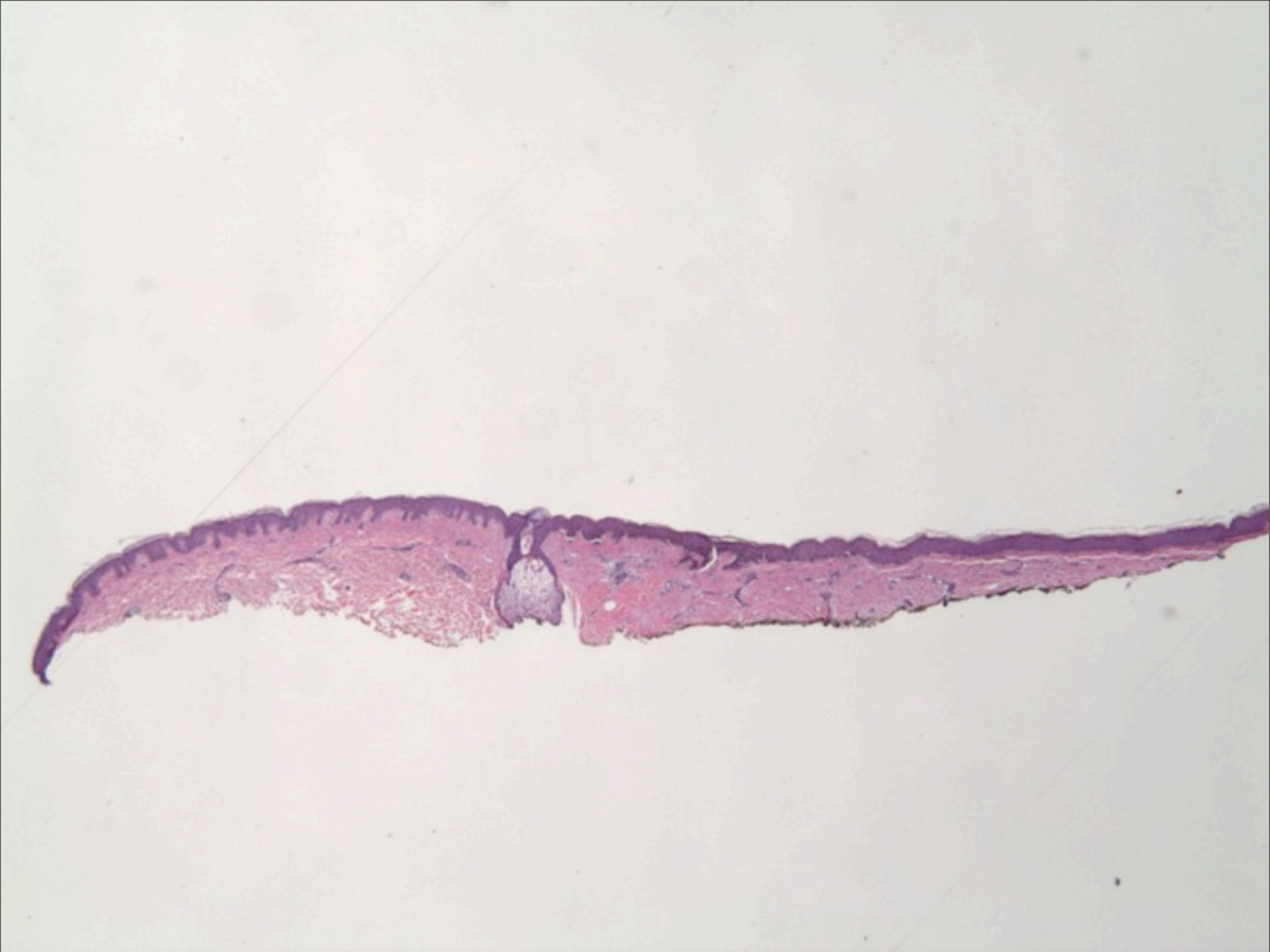Neoplasm extends close to the edge of the specimen, and the area of the margin is obscured by electrocautery or other artifact

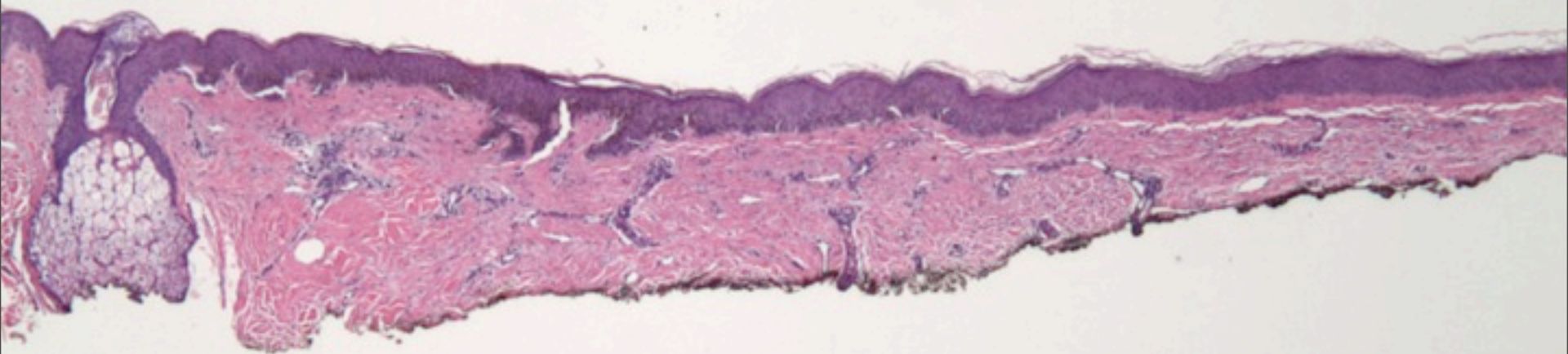


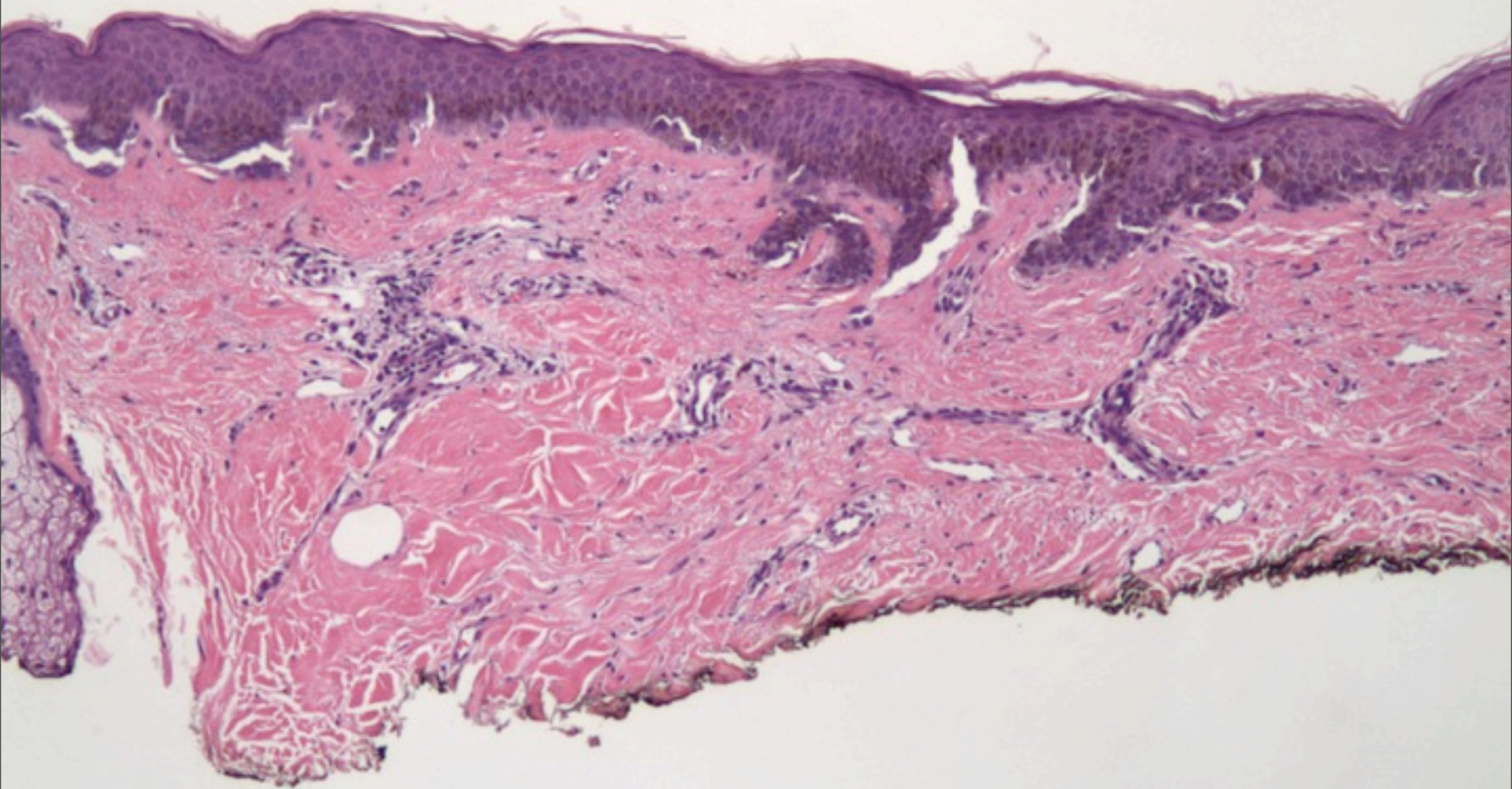


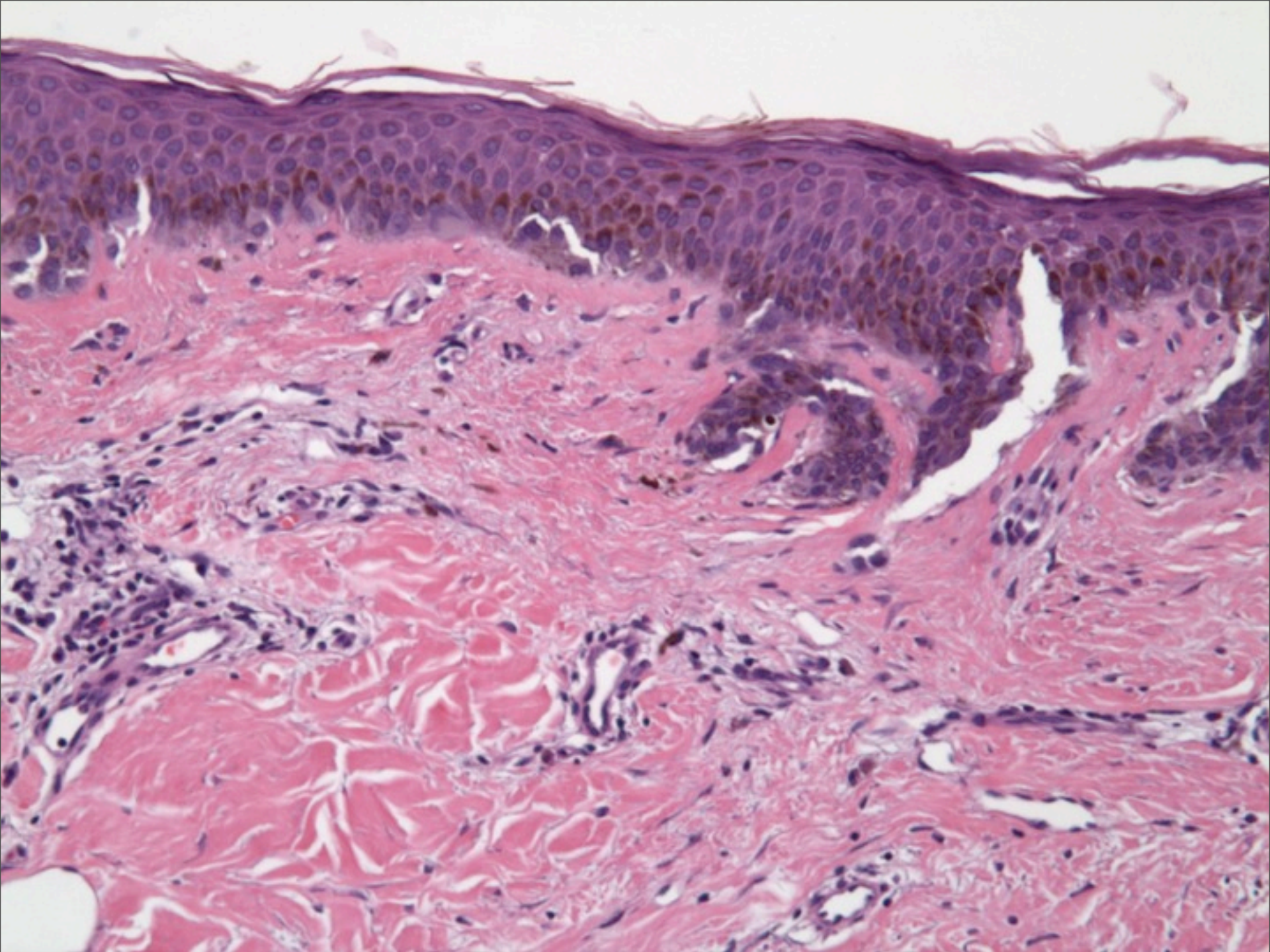


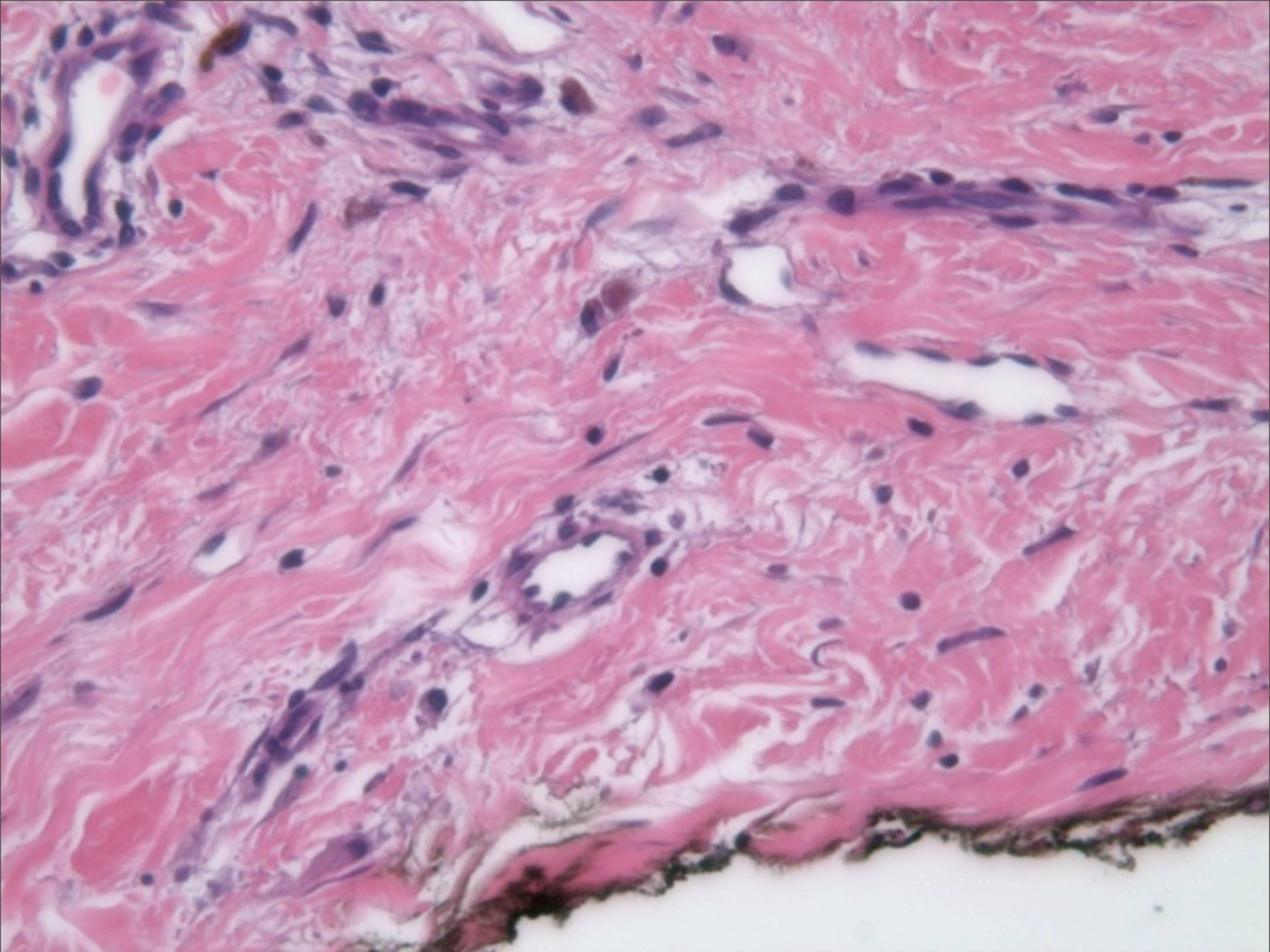
Neoplasm extends close to the edge of the specimen, and part of the tissue at the margin is out of the plane of section



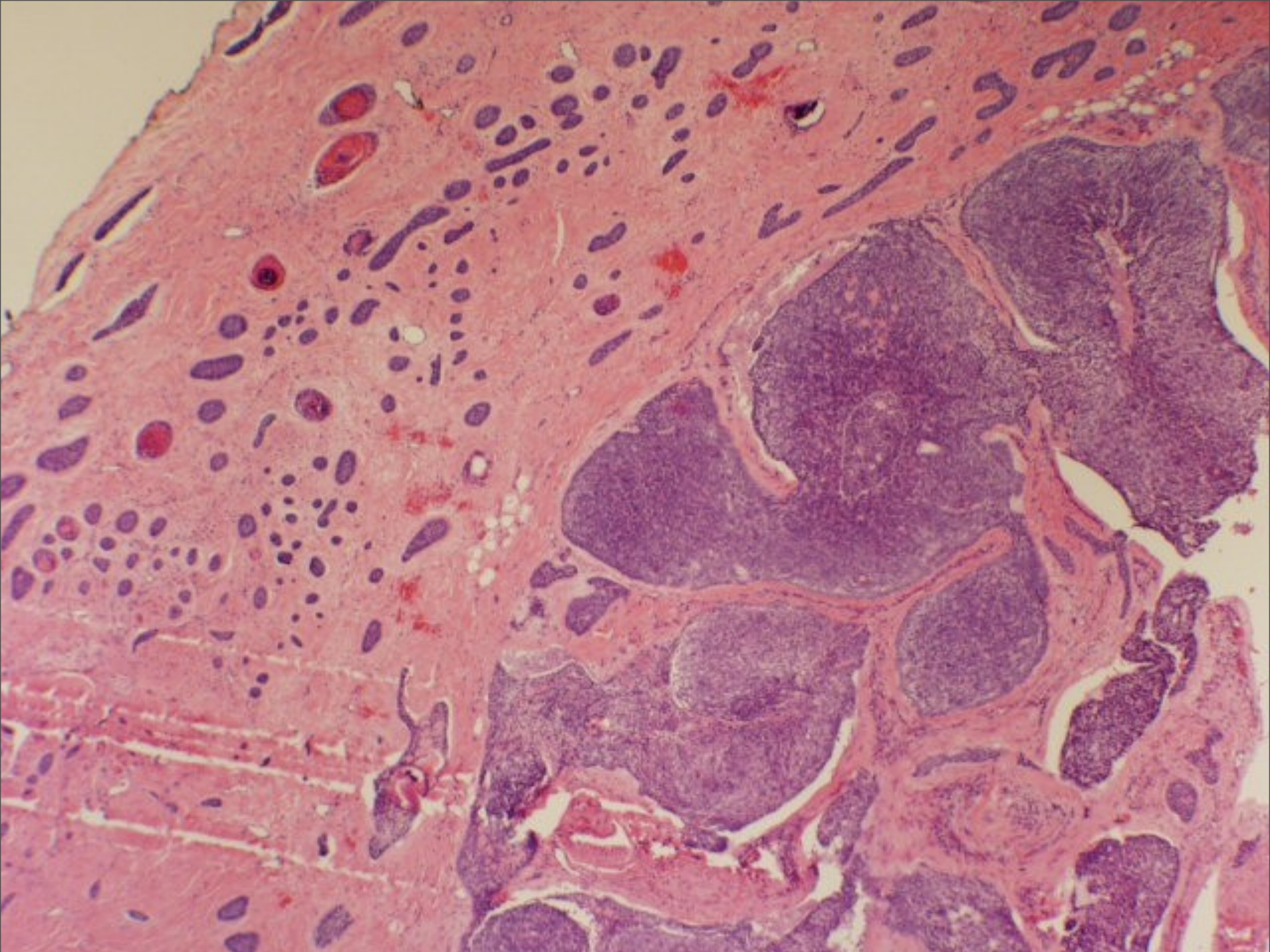


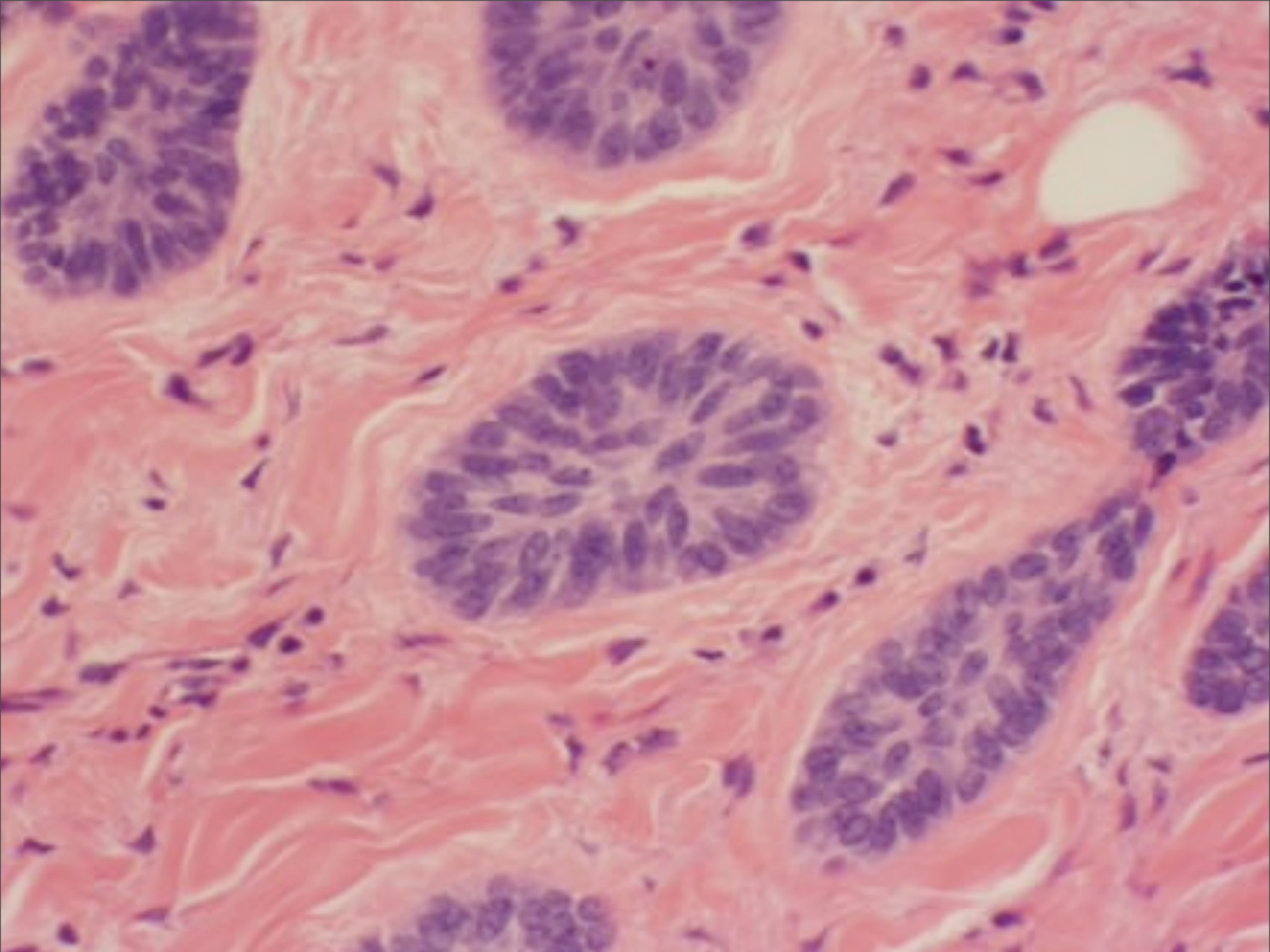


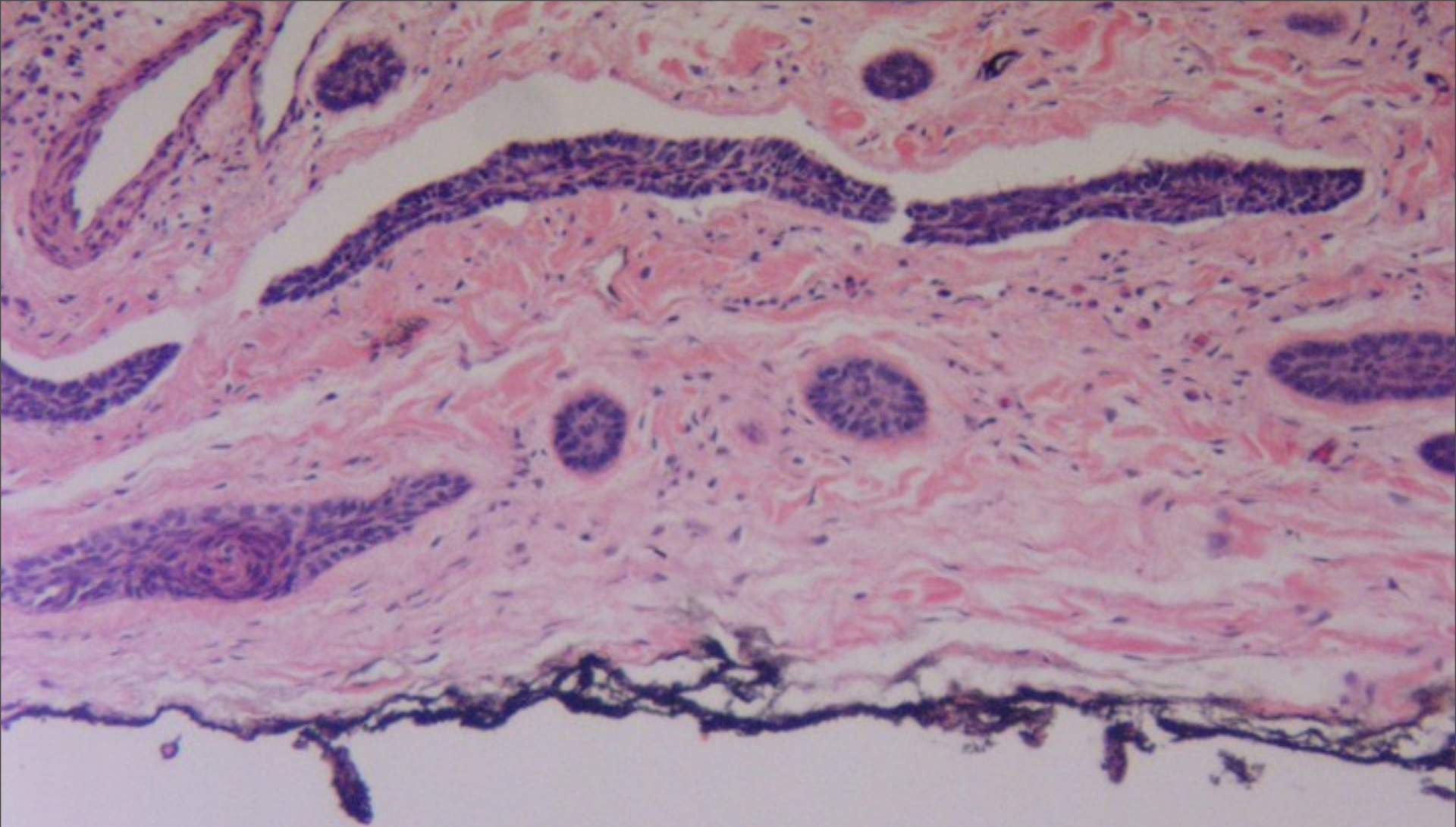


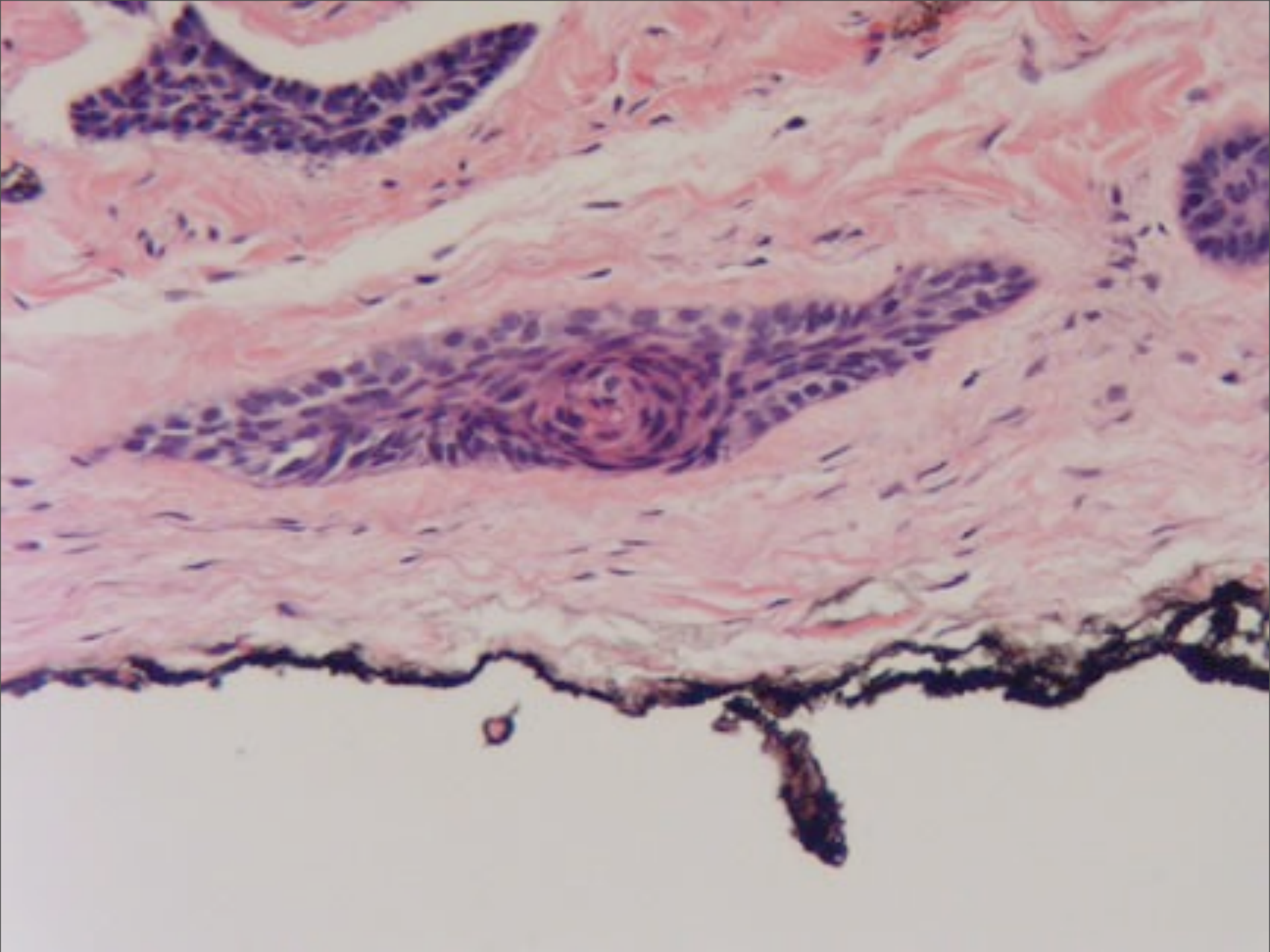


Neoplasm extends close to the edge of the specimen, and a scar is present between the neoplastic cells and margin

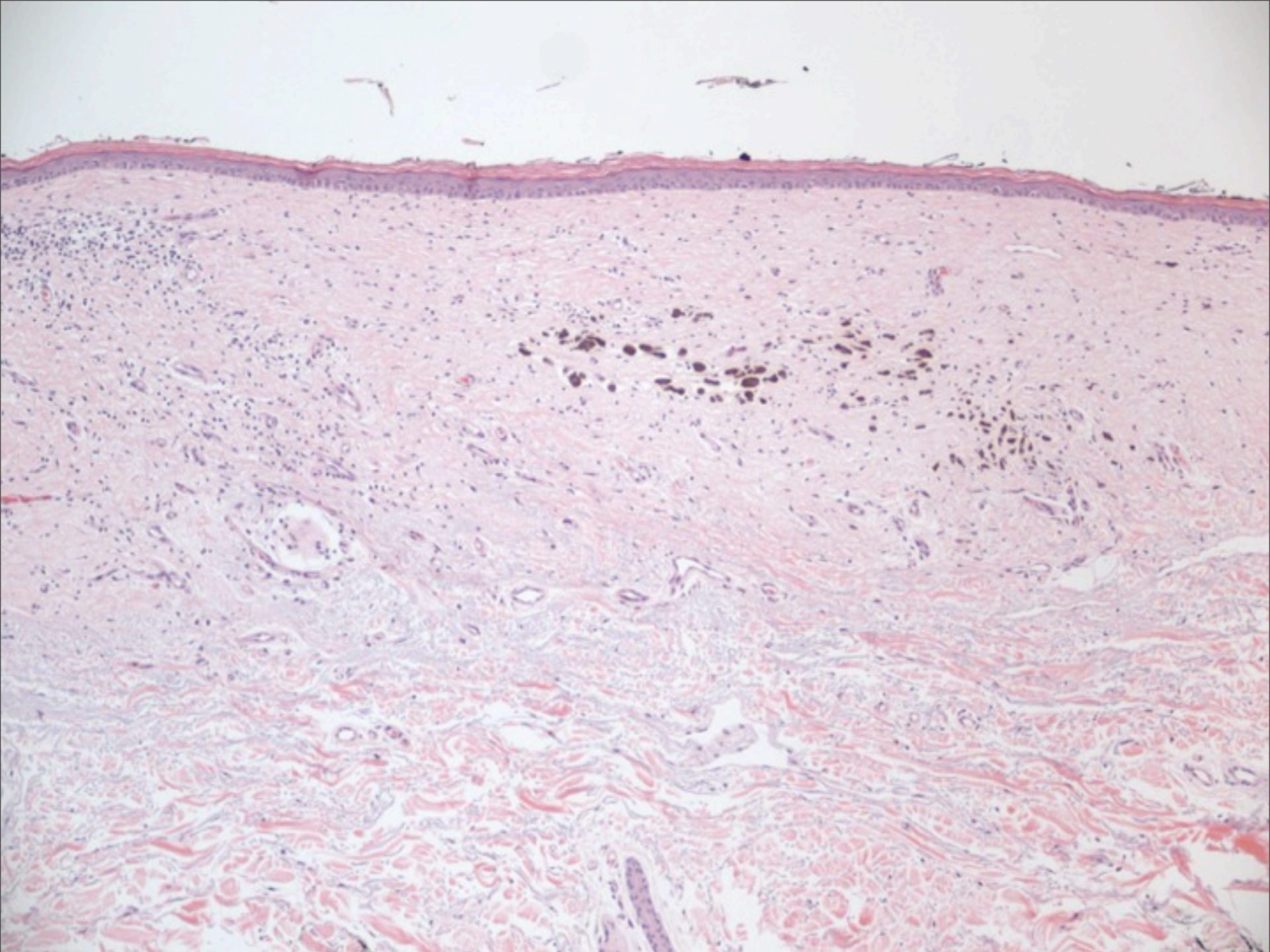


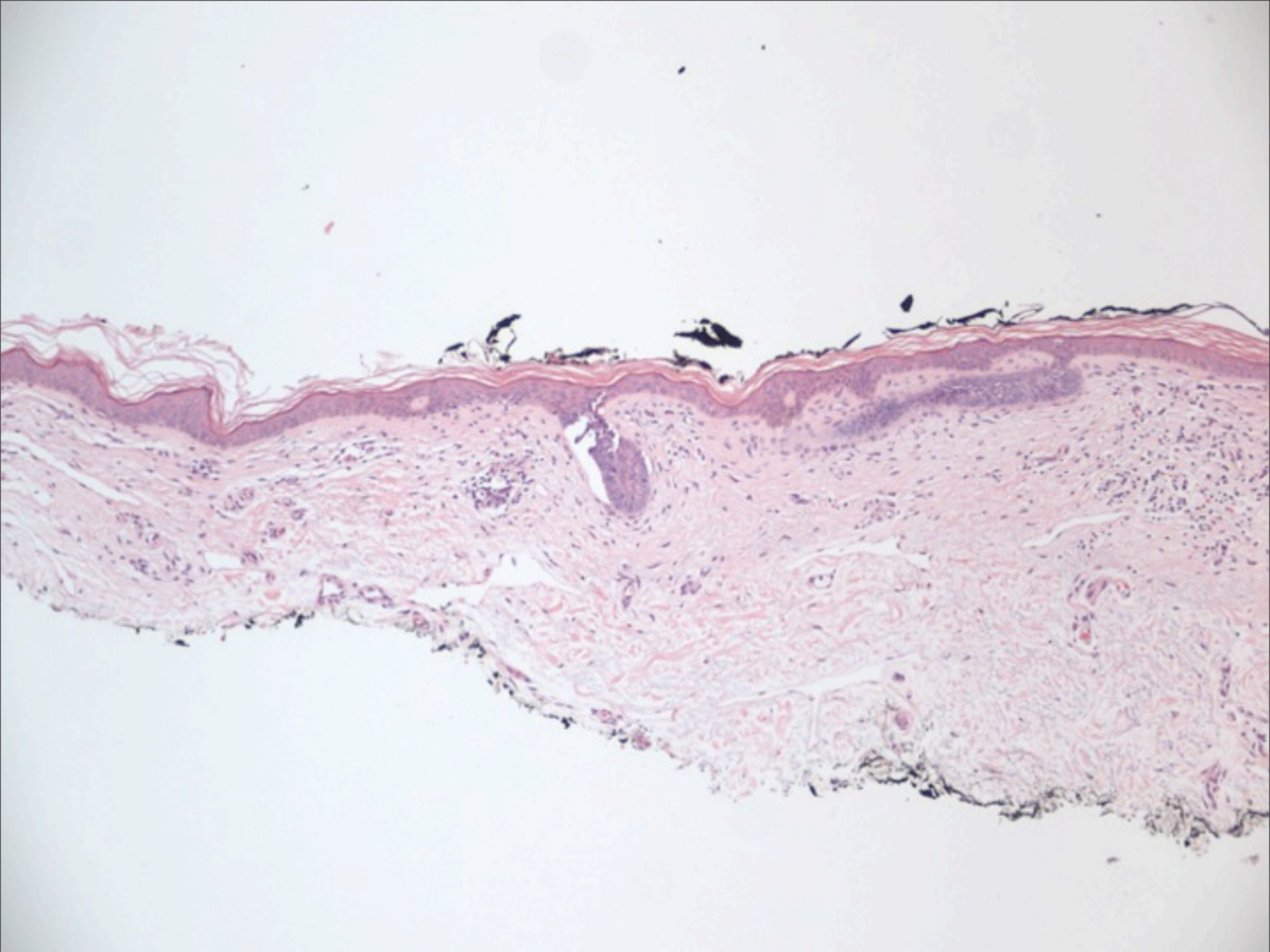


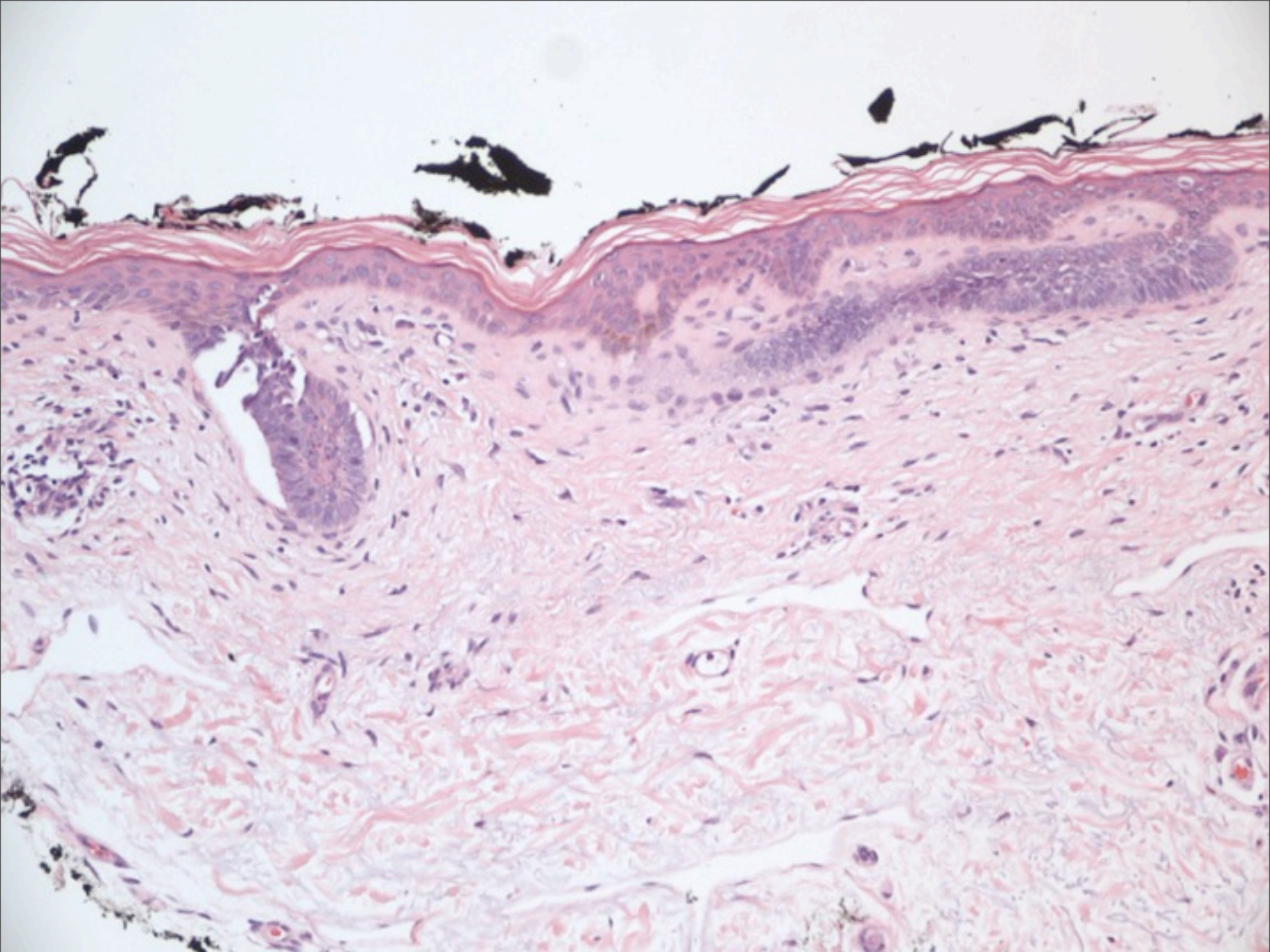


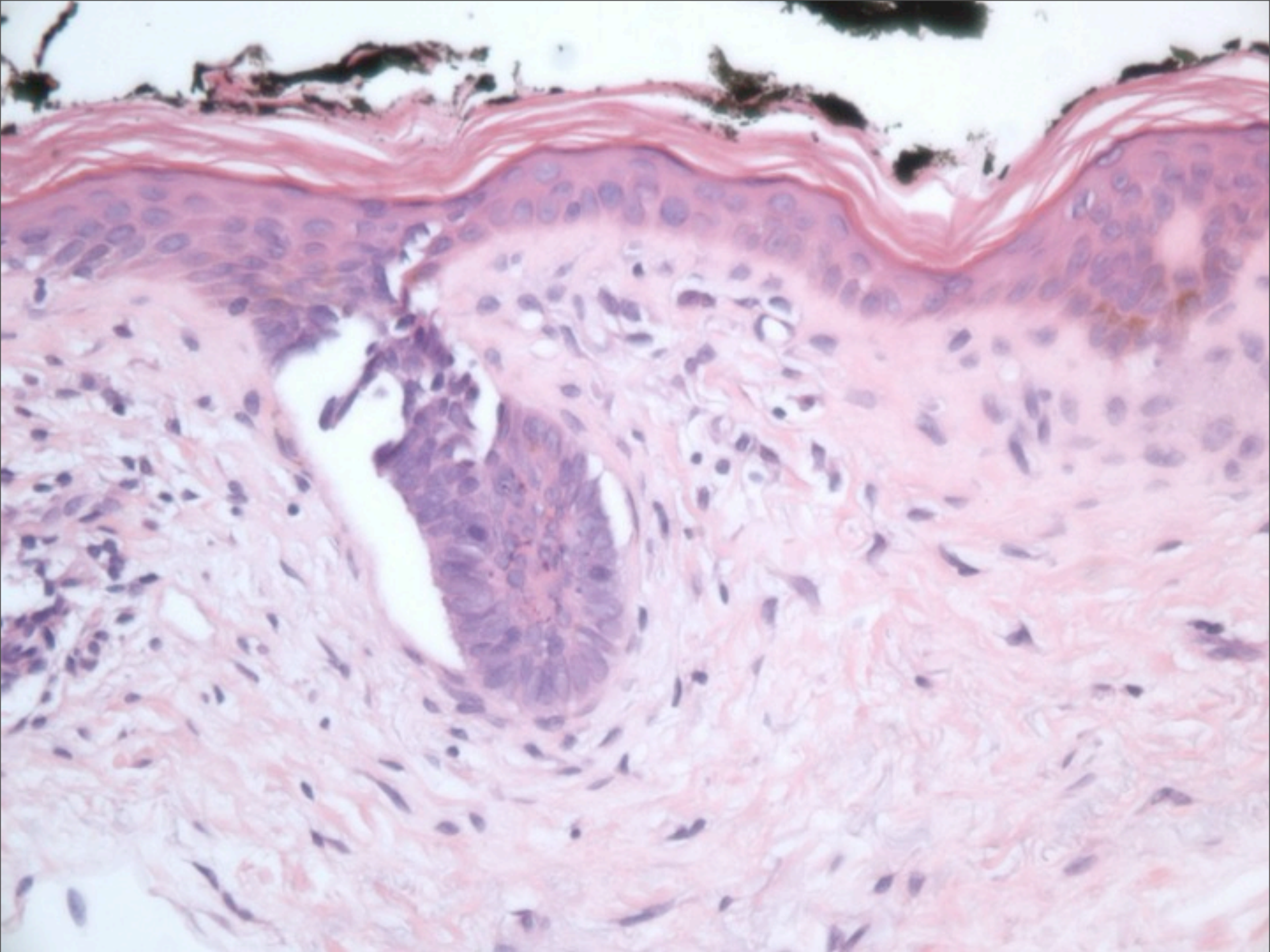


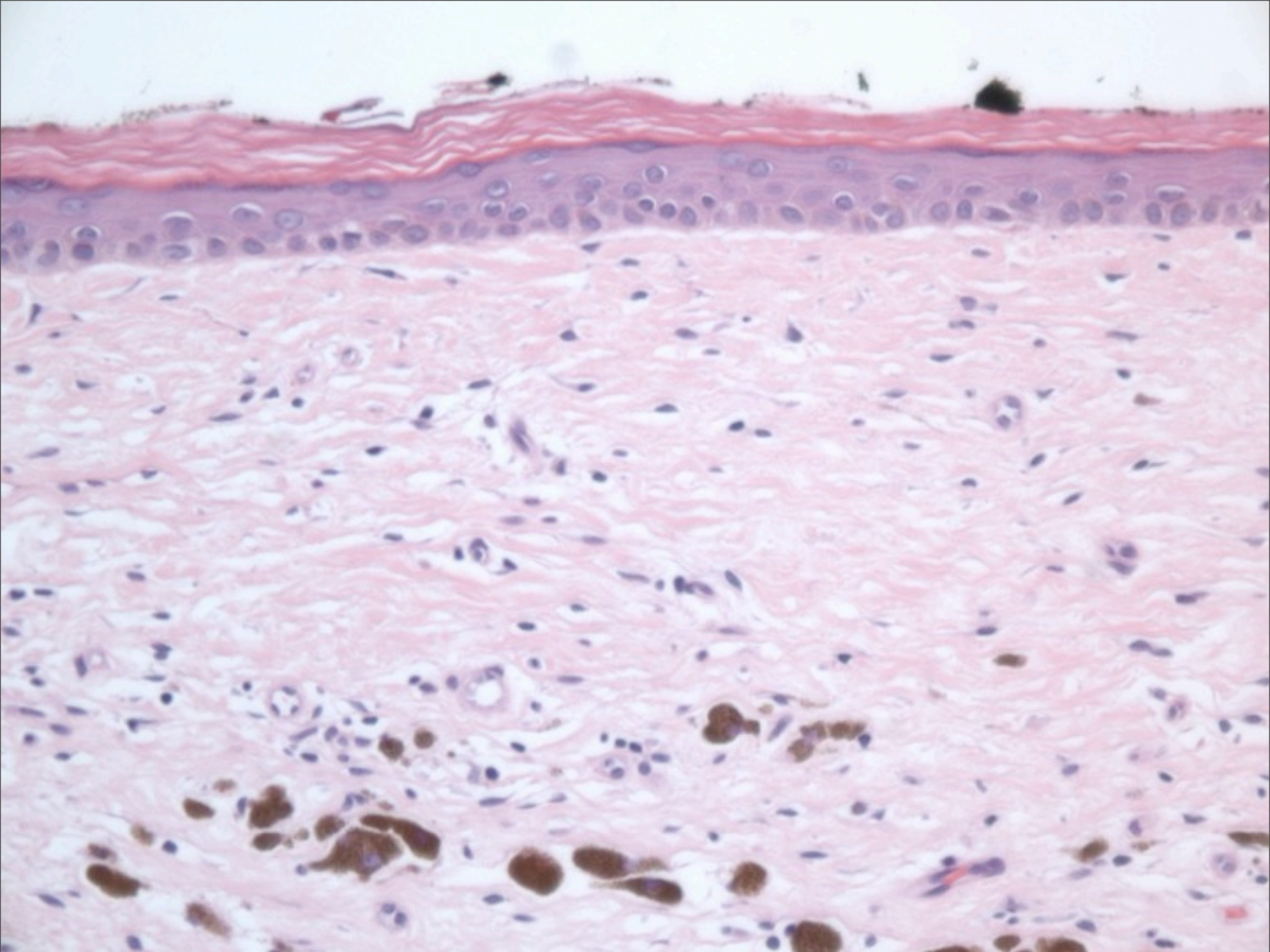
Distance between nests of a dermal neoplasm (eg basal cell carcinoma) is anywhere close to that between the most lateral, or deepest nest and the margin



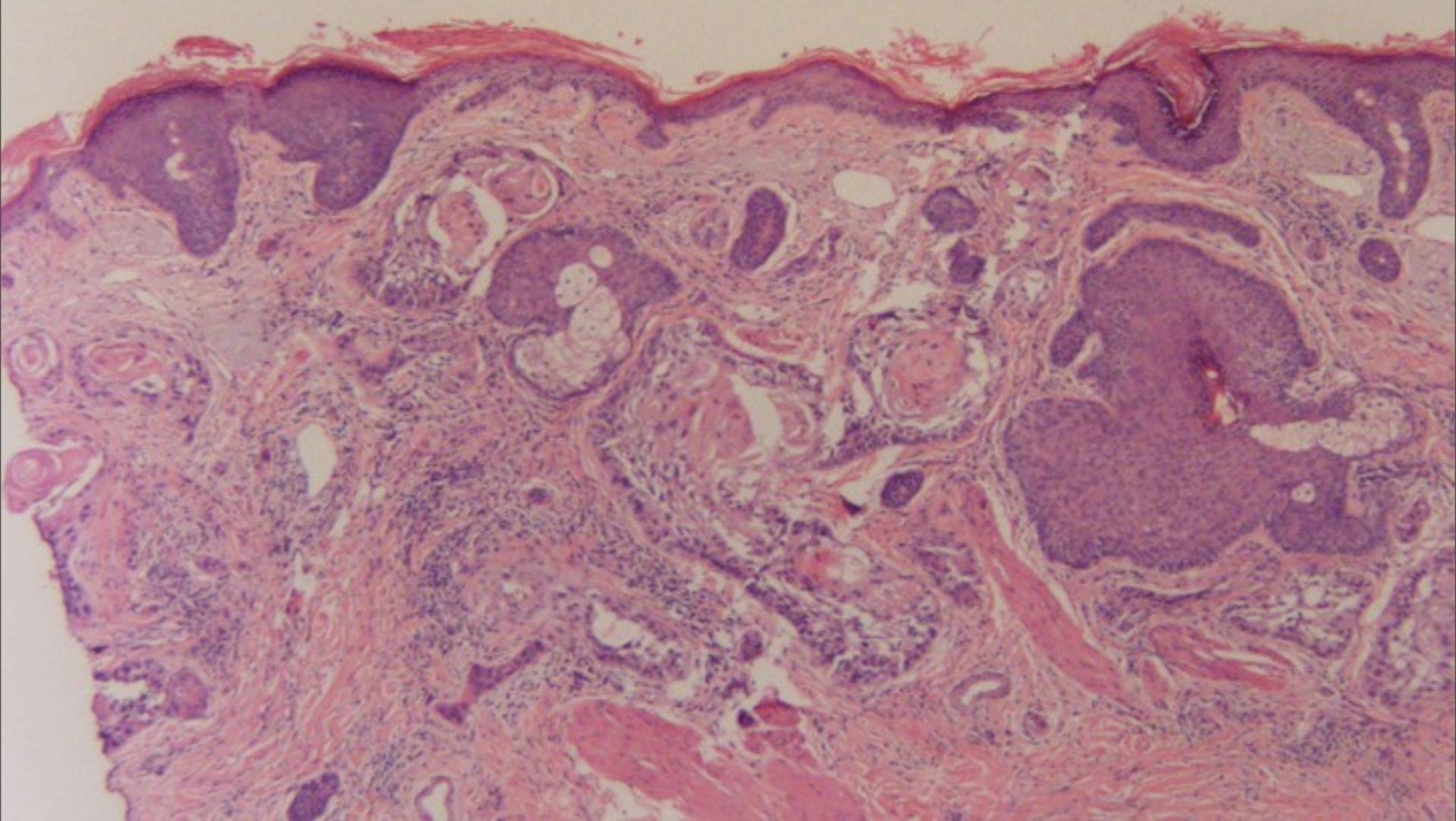




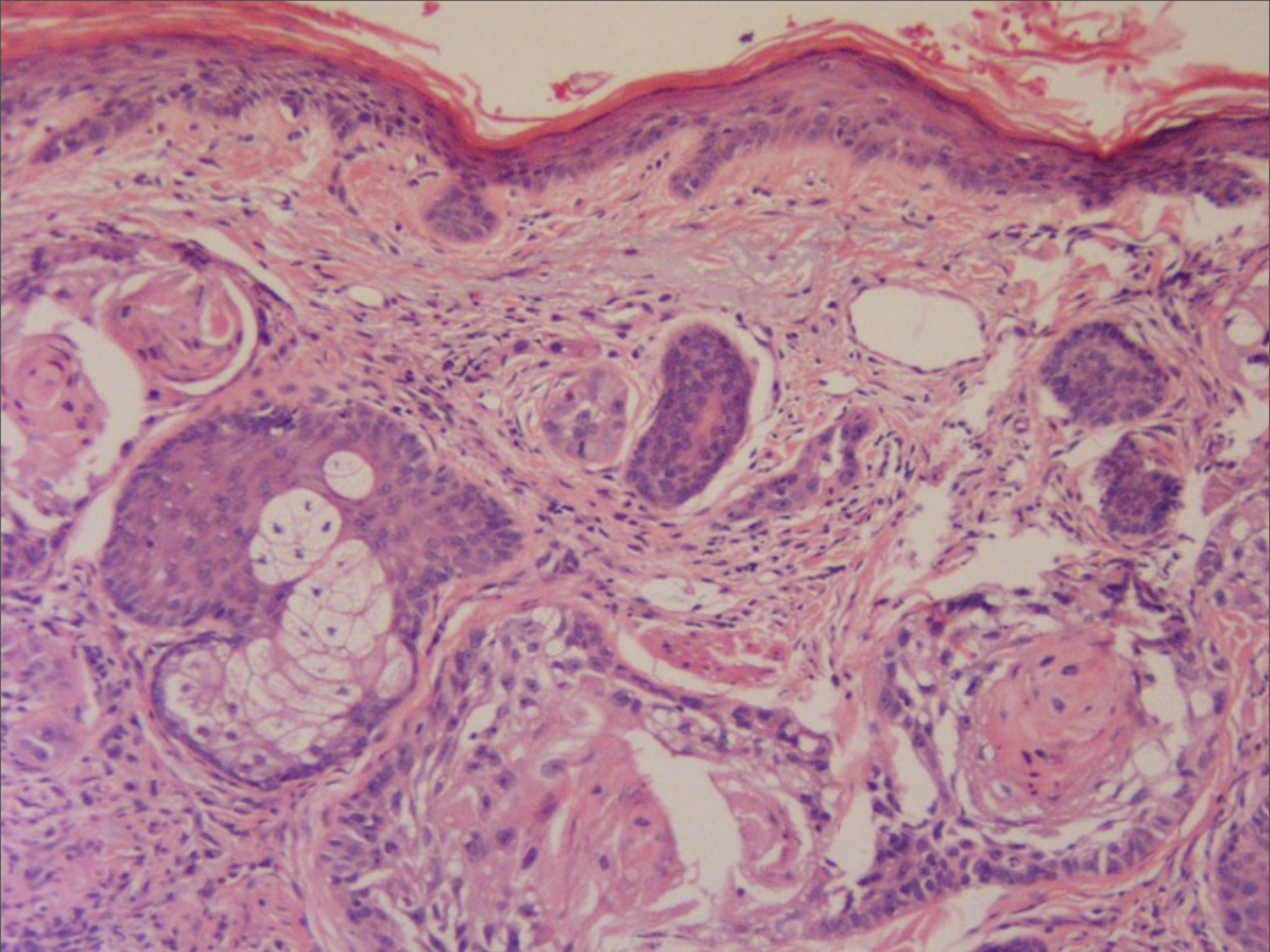


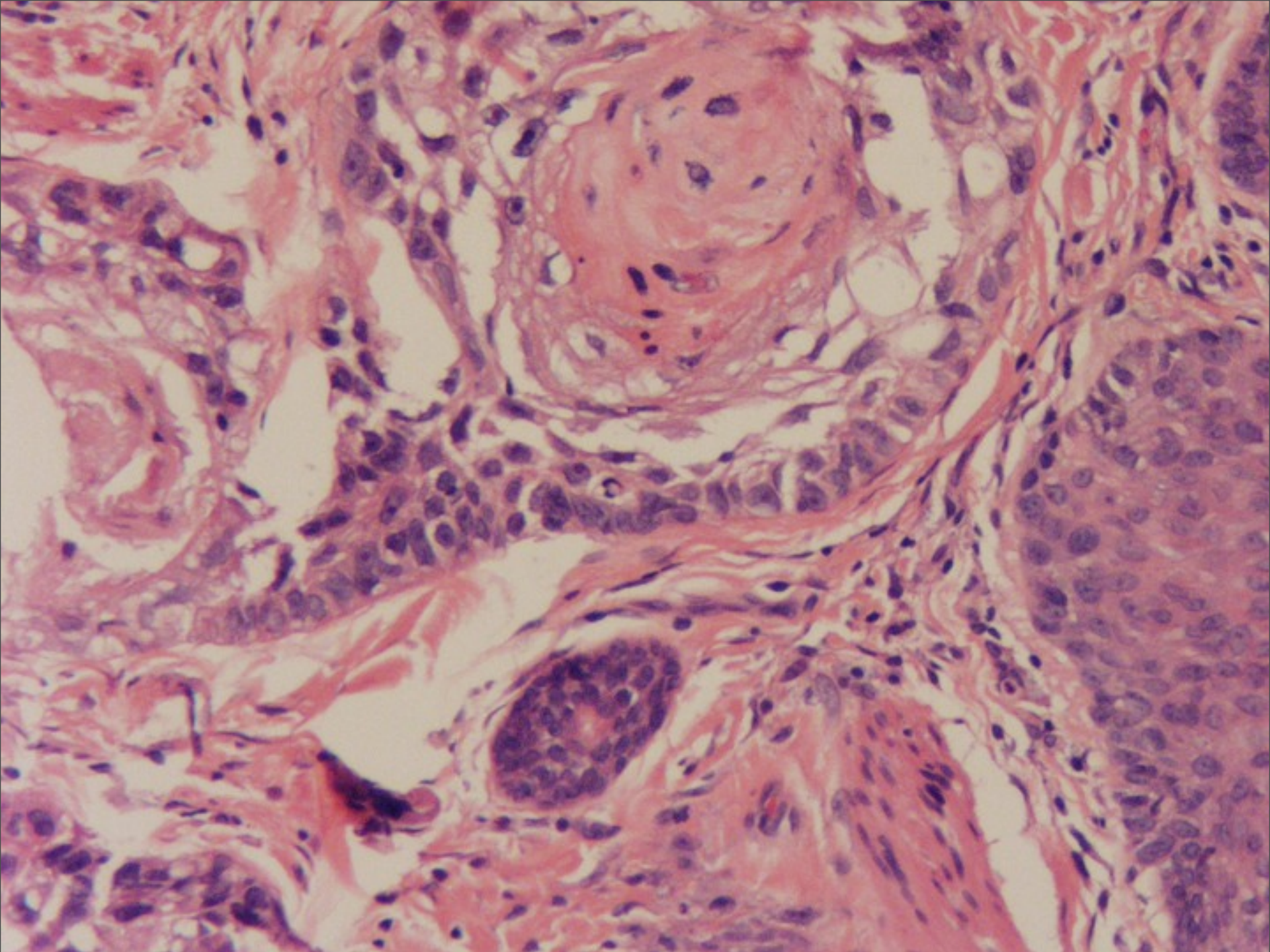


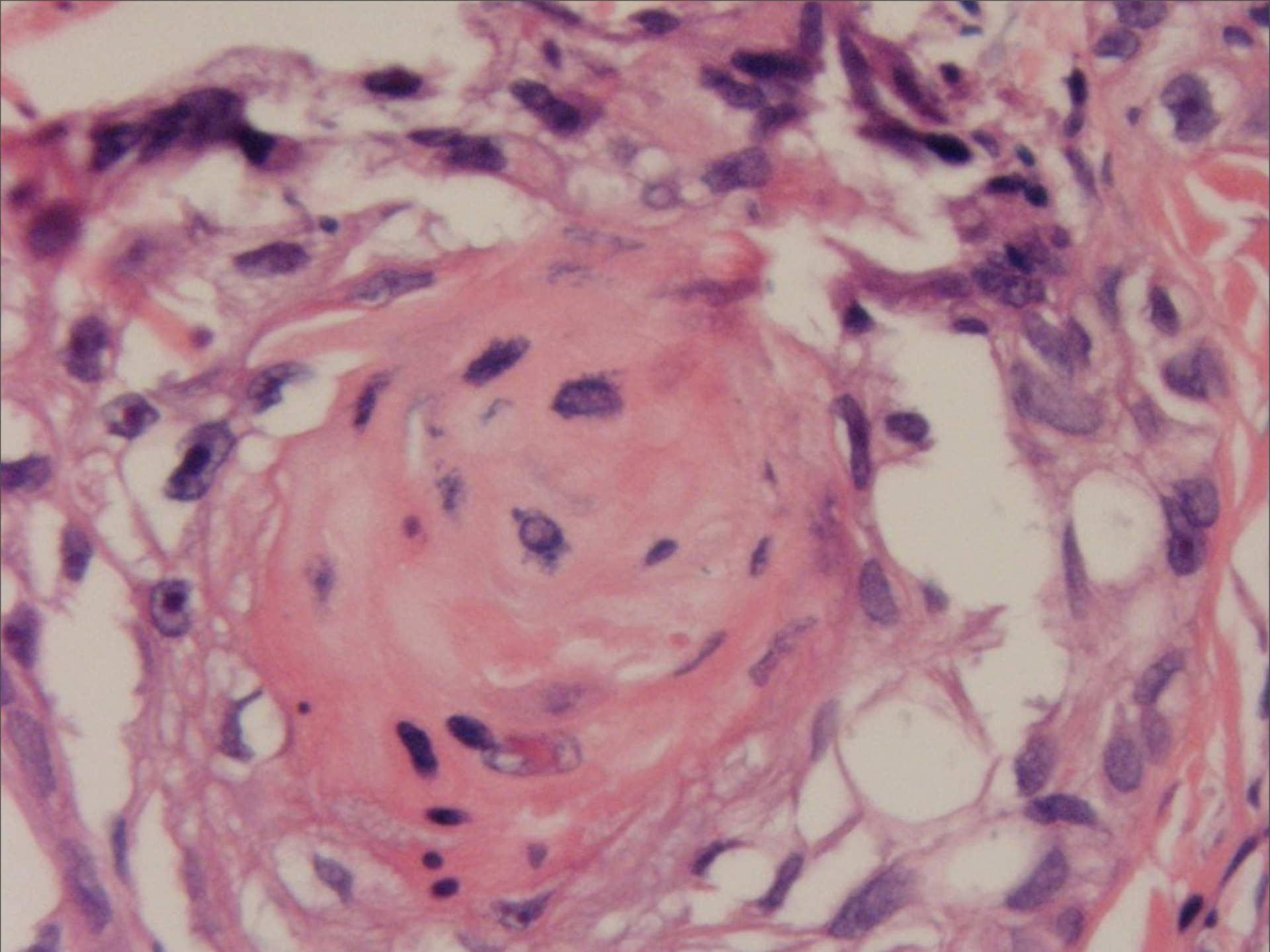
Stroma seen between the nests of a neoplasm (eg the fibrosing granulation tissue-like stroma of a superficial BCC) is present between a nest of neoplastic cells and the margin



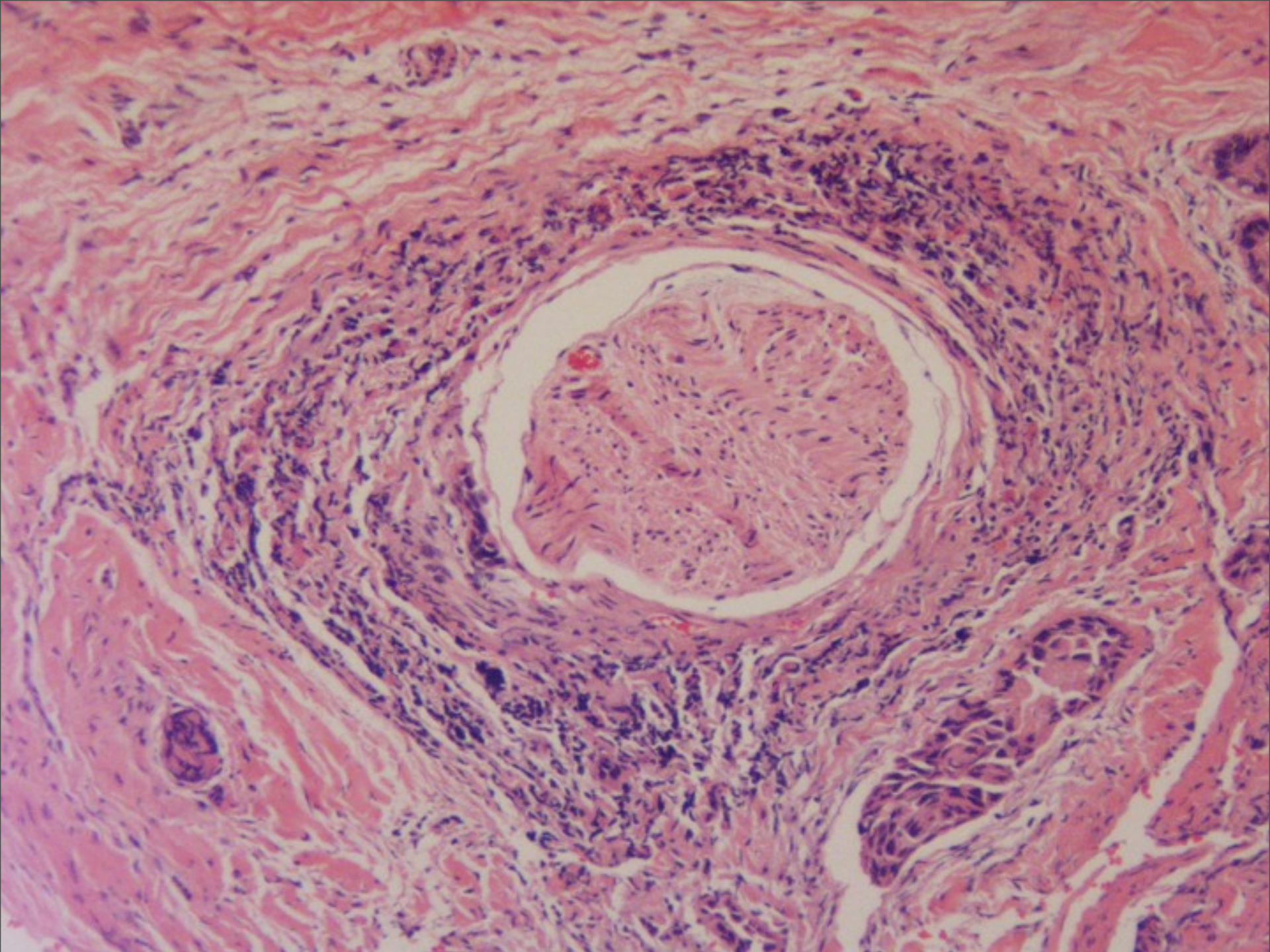
Wednesday, July 18, 12



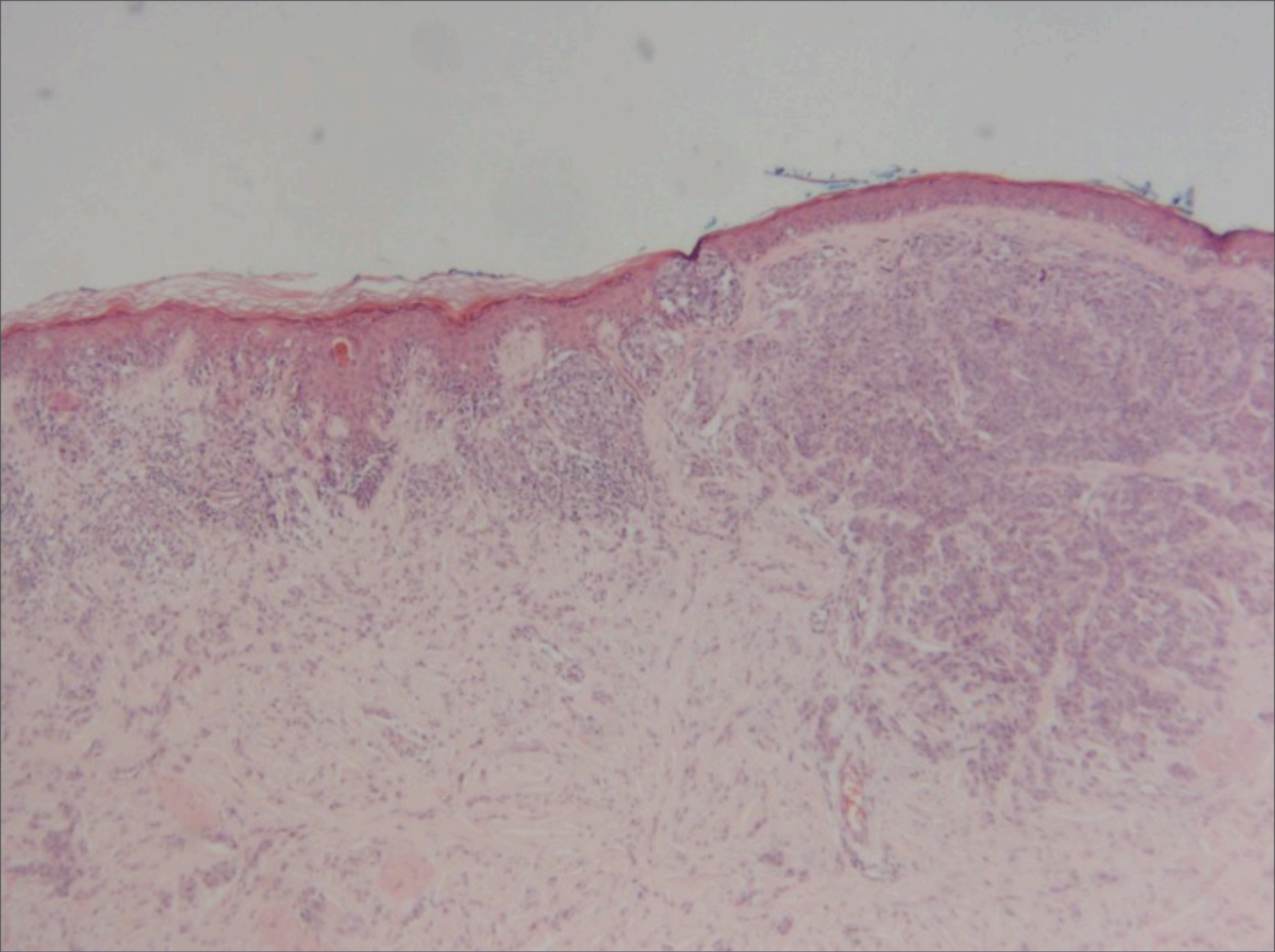


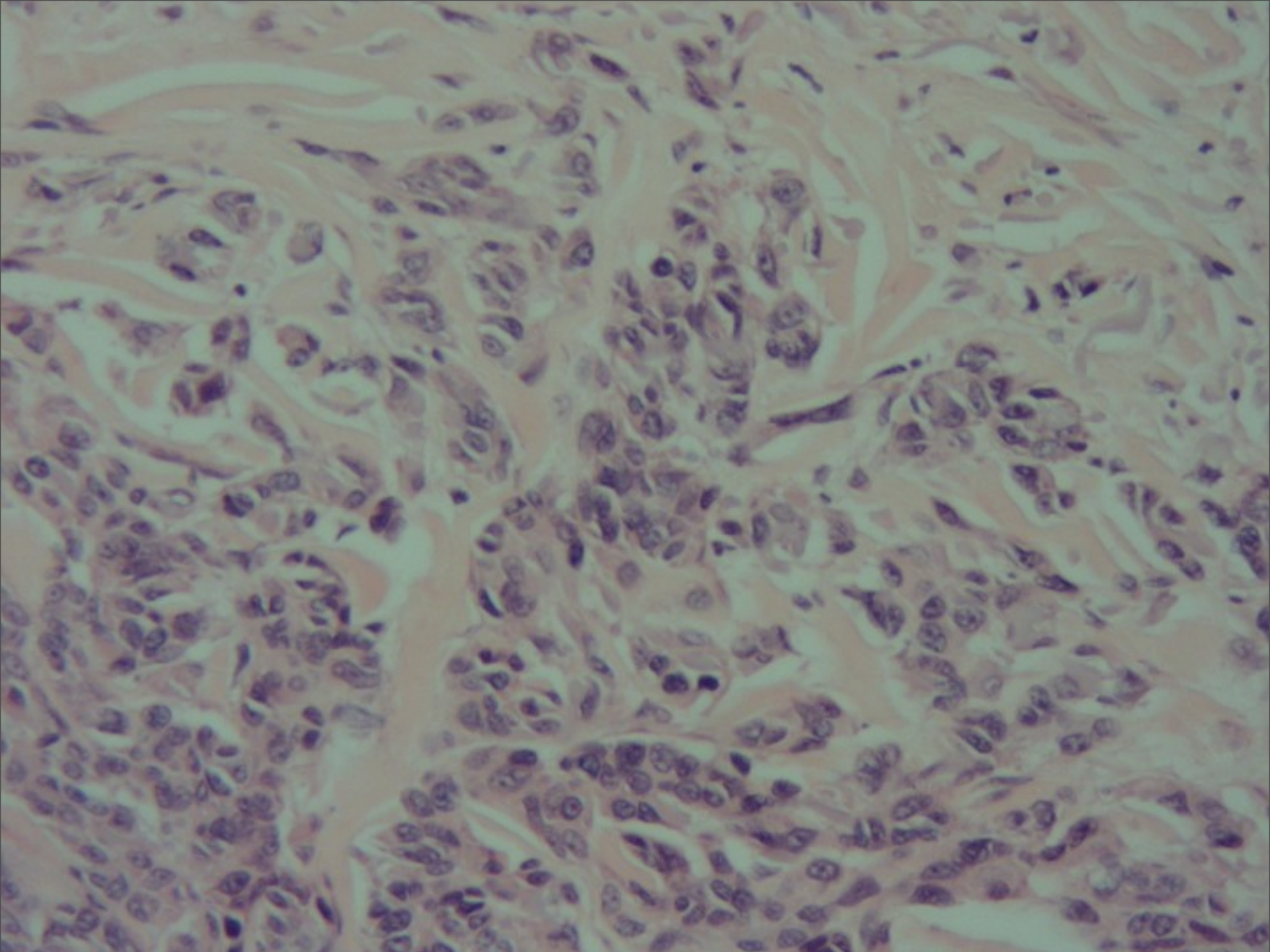


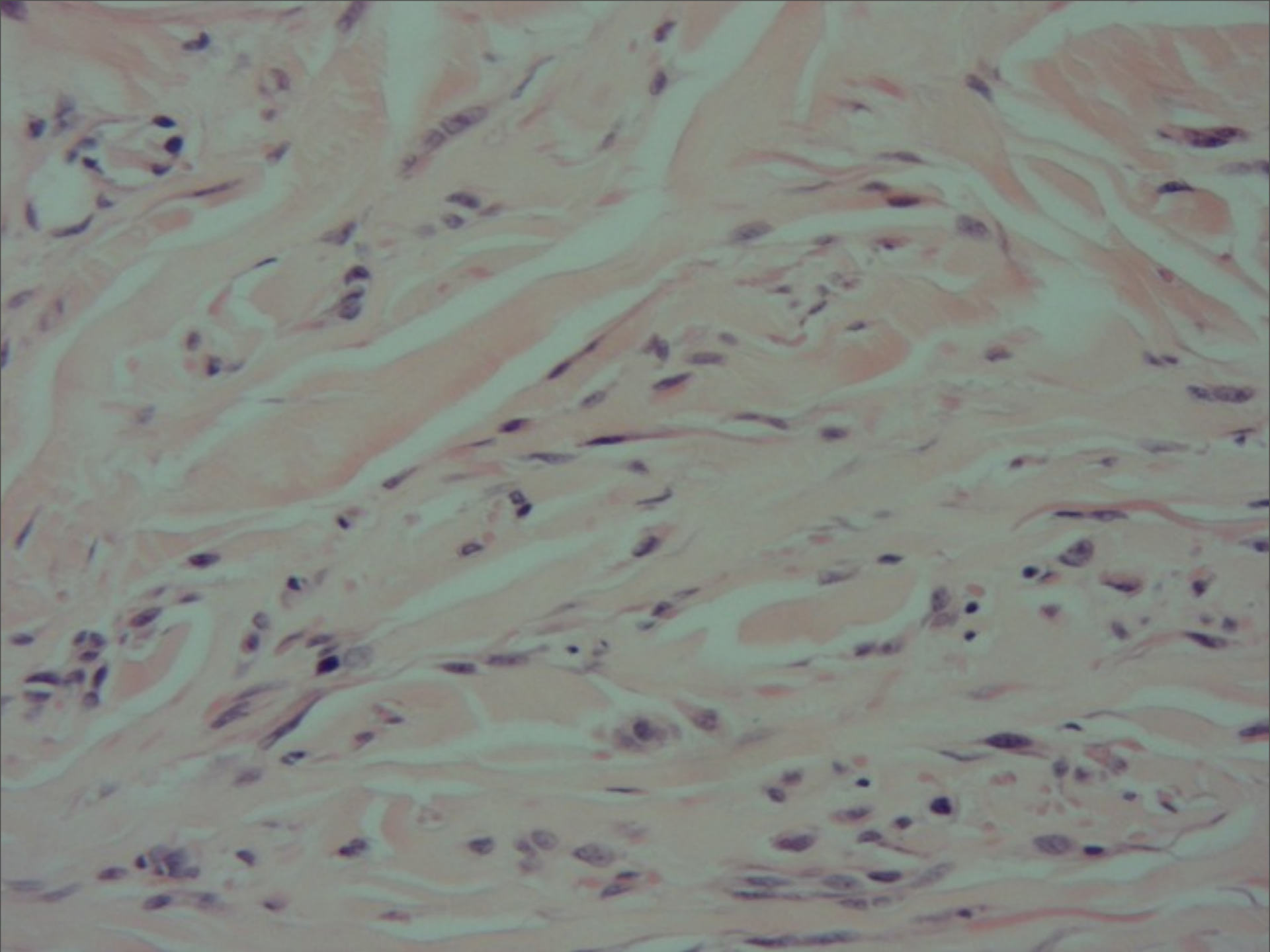
Wednesday, July 18, 12

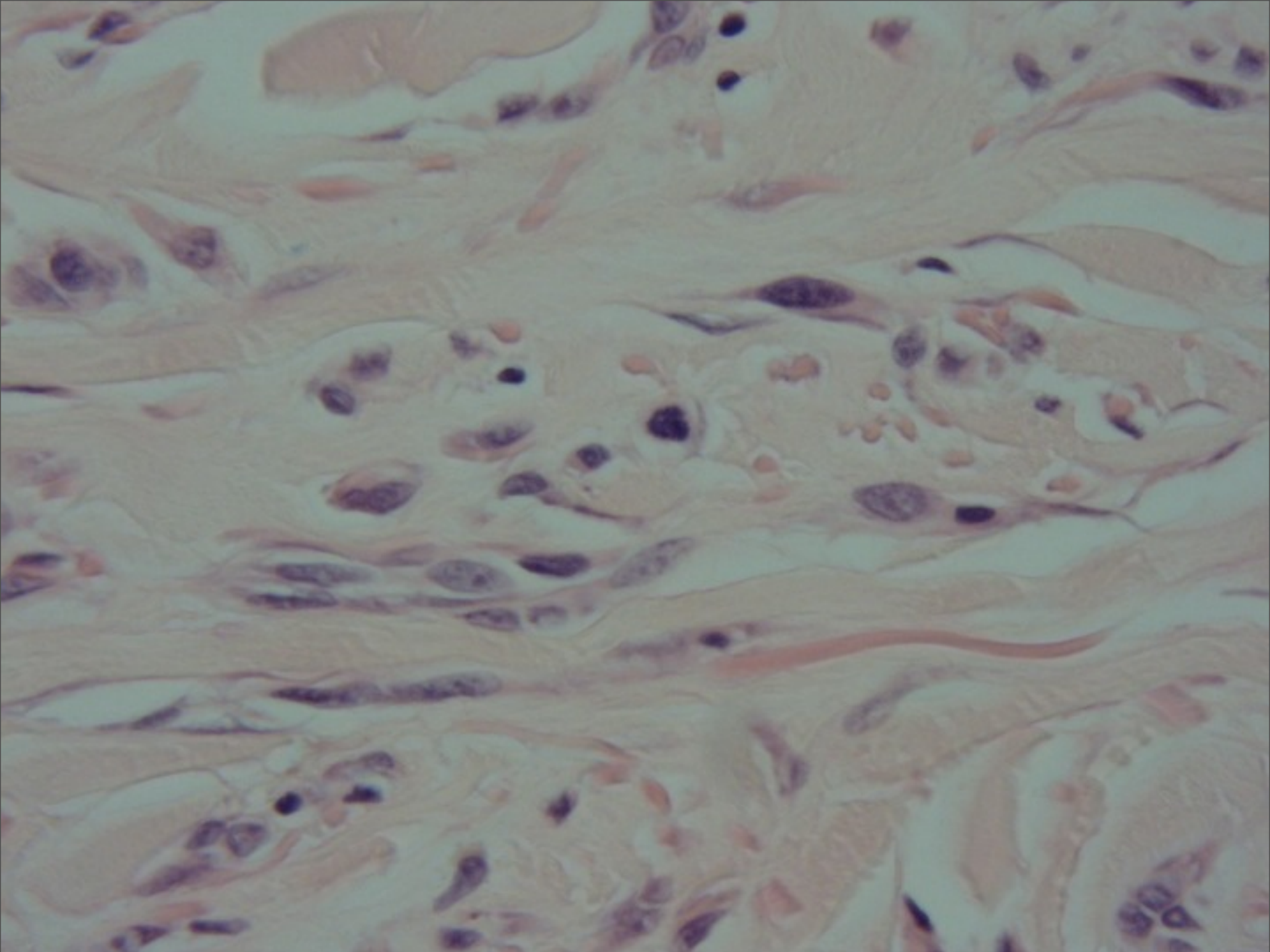


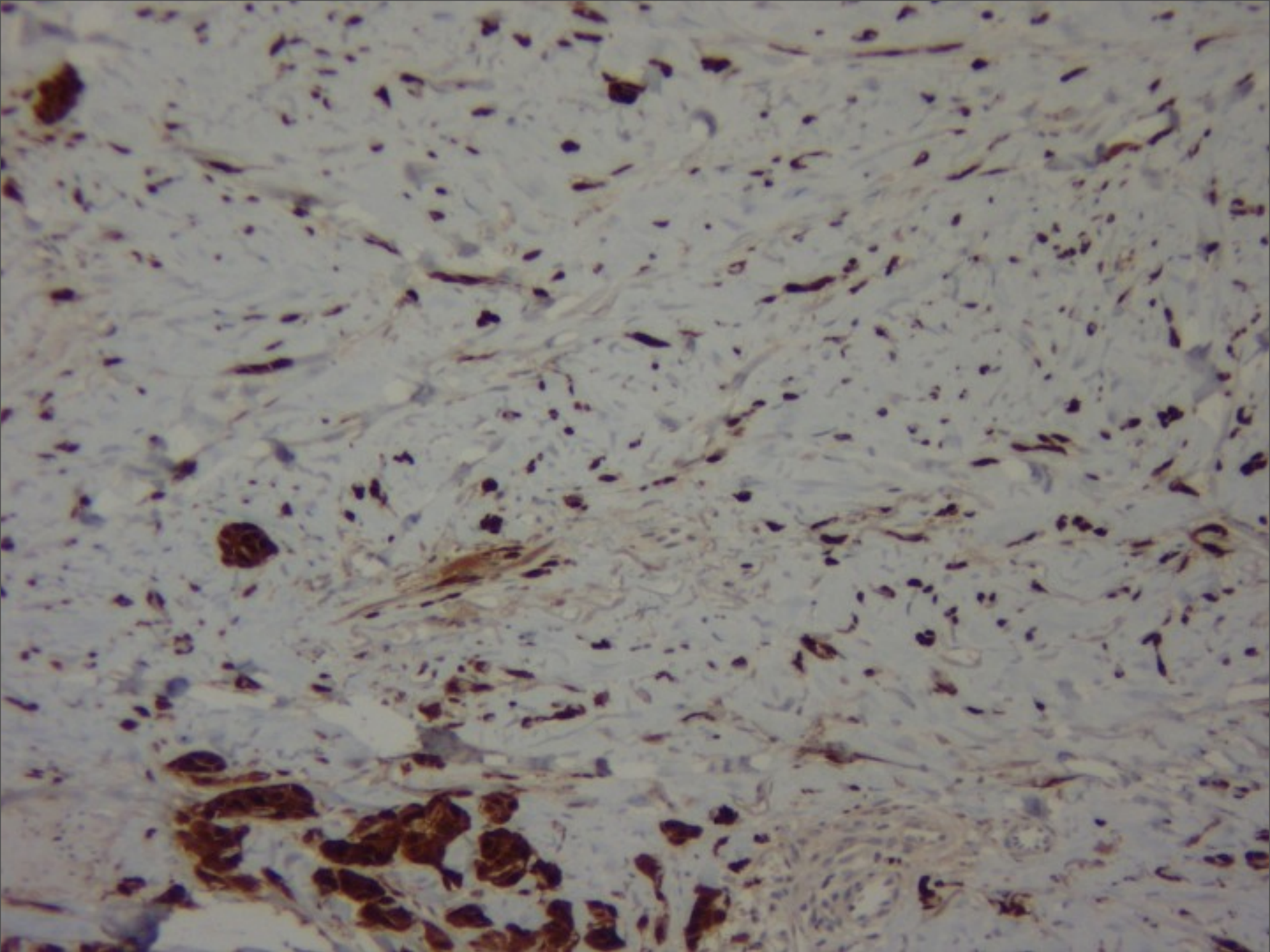
Perineural invasion is present anywhere
close to a margin



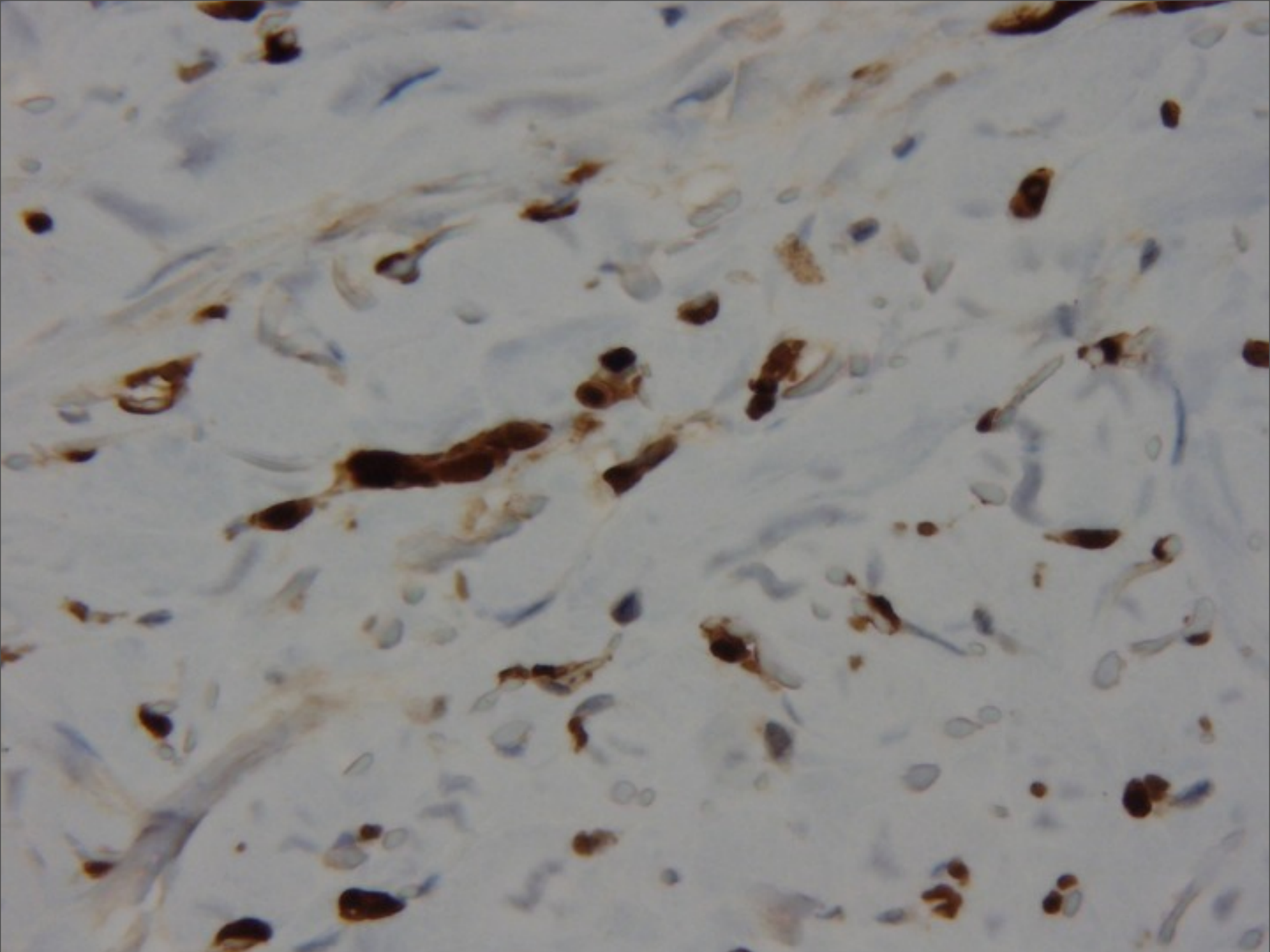






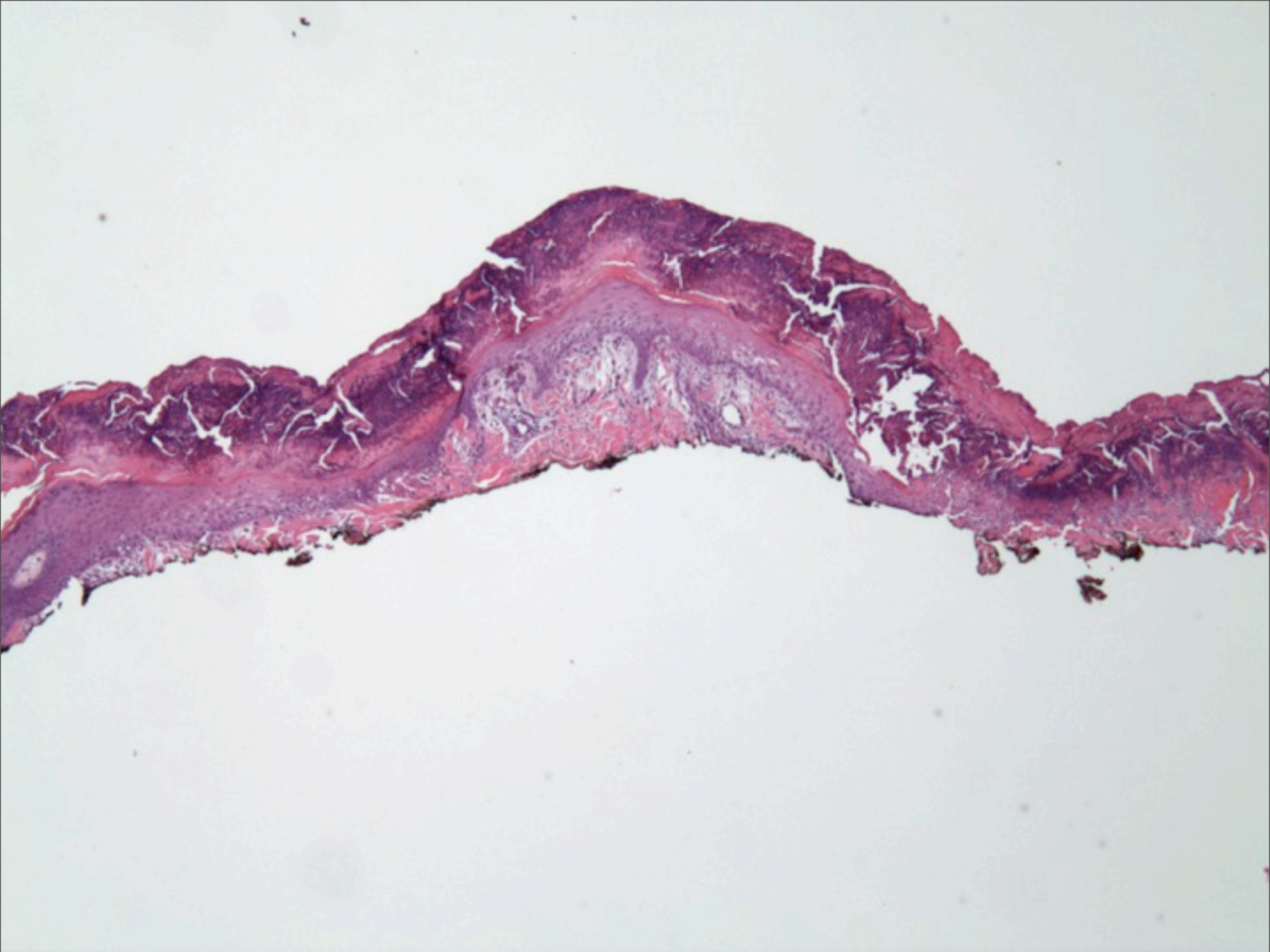


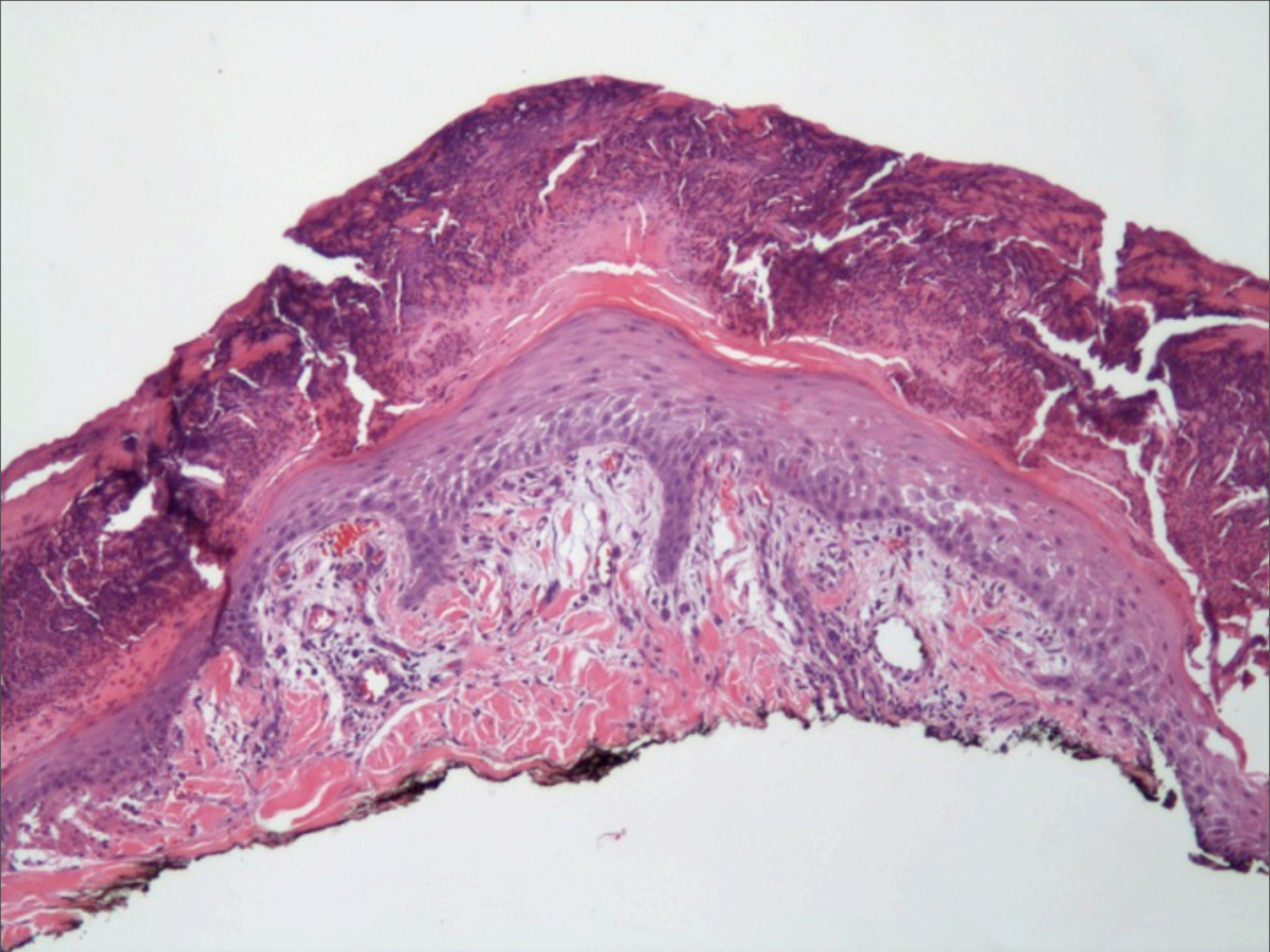
Wednesday, July 18, 12

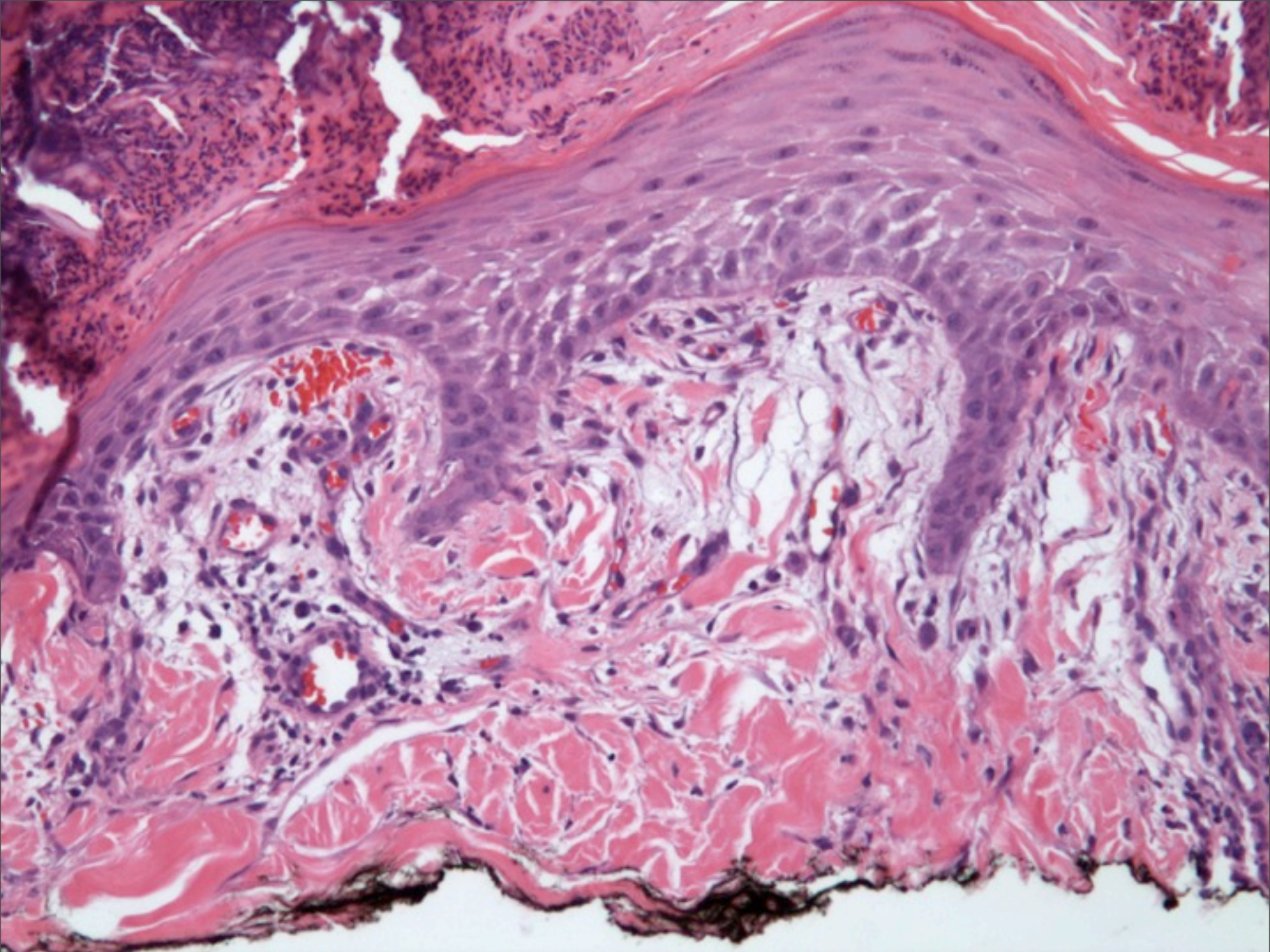


Wednesday, July 18, 12

A neoplasm is so subtle (eg desmoplastic melanoma) that IPOX staining should be employed to distinguish between fibrosis around a biopsy site and residual neoplasm







An ulcer produced by curettage (to determine the size of a subsequent excision) extends to the edge of the specimen

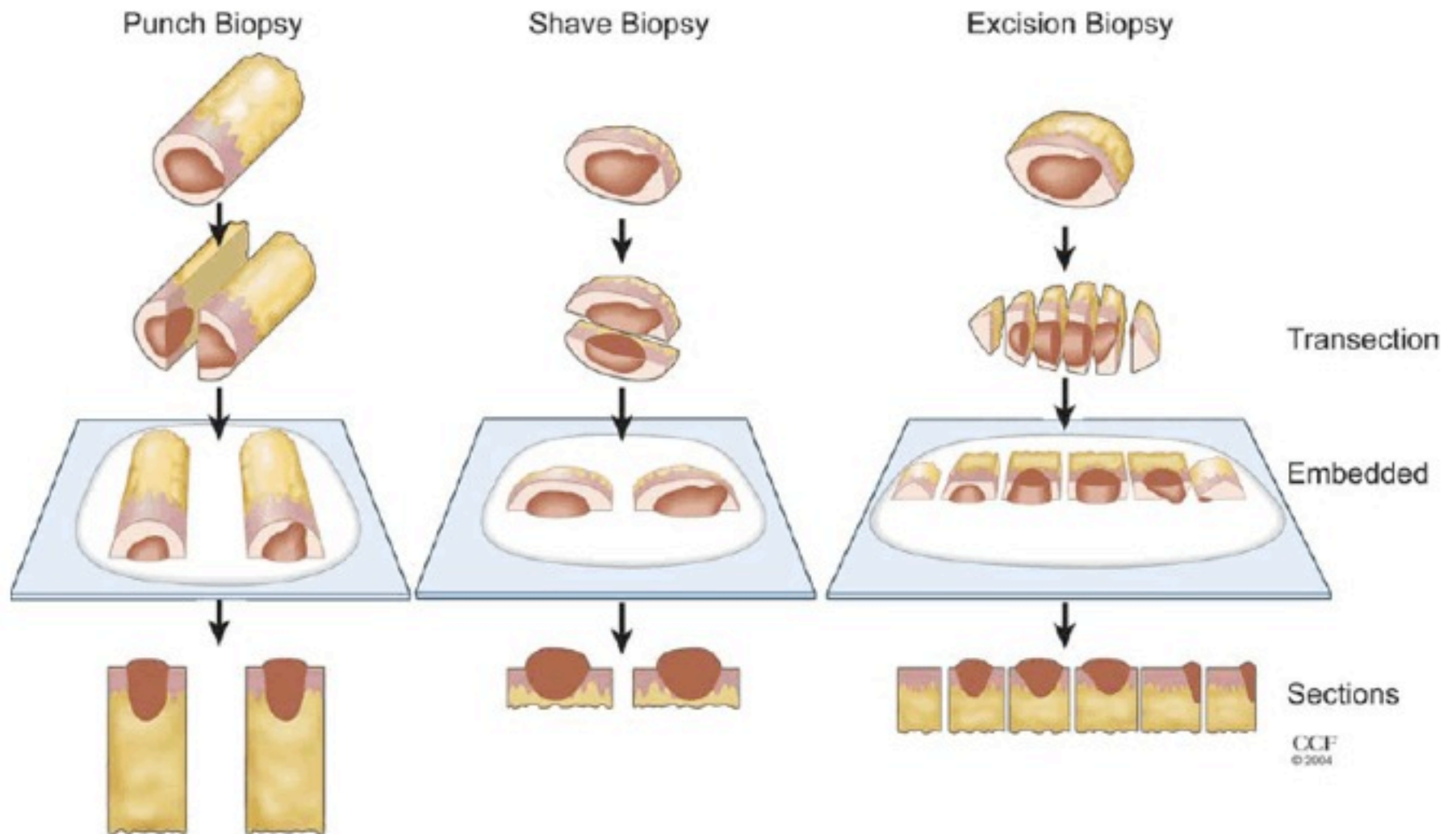
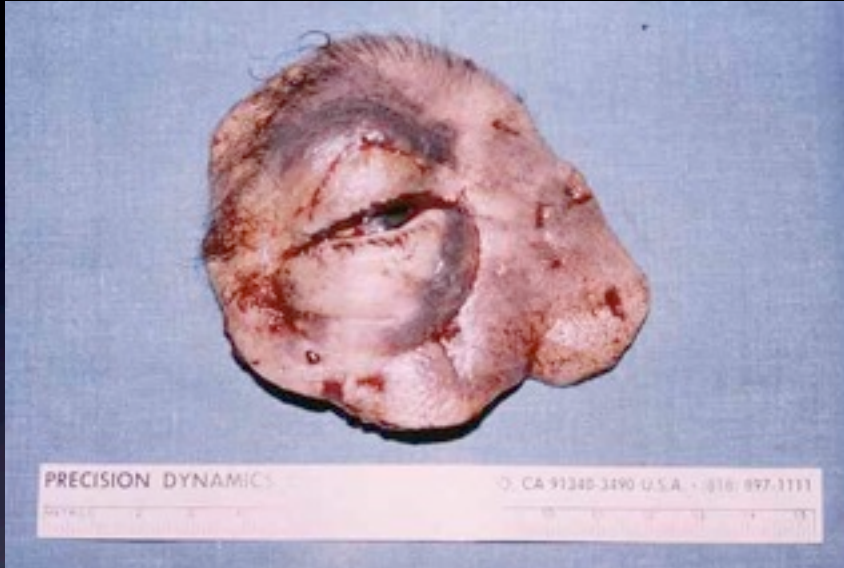

Fig 1. Comparison of a punched, shaved, and excised melanocytic lesion and the histologic steps of processing demonstrates that elliptical excisions are best suited for adequate margin evaluation. On gross examination (*top*), the nevus is present at the surgical margin in all three types of biopsies. Upon sectioning (*bottom*), however, involved surgical margins are only noted in the nevus, which was removed by an elliptical excision.

In our opinion, negative margins should only be reported in elliptical excisions and not in lesions

Sellhyer K. and Bergfeld WF

Questions



- *I was going to have cosmetic surgery until I noticed that the doctor's office was full of portraits by Picasso.*

Rita Rudner

References

- Leboit PE. Am J Dermatopathol 2004;26:259-262.
- Huang CC and Boyce SM. Semin Cutan Med Surg 2004;23:167-173.
- Sellhyer K. and Bergfeld WF. J Am Acad Dermatol 2005;52:1095-1097
- Sellheyer K, Bergfeld WF, Stewart E, Roberson G, Hammel J. *J Cutan Pathol.* 2005 Apr;32(4): 293-9.